

# Buschke Löwenstein tumor (BLT)/giant condyloma acuminatum (GCA): An immunopathogenesis insight



Paulus Mario Christopher<sup>1\*</sup>, Hartono Kosim<sup>1</sup>, Ratna Sari Wijaya<sup>1</sup>, Silvi Suhardi<sup>2</sup>, Linda Julianti<sup>2</sup>

## ABSTRACT

Buschke Löwenstein tumor (BLT)/giant condyloma acuminatum is a rare variant of sexually transmitted infection caused by human papillomavirus (HPV) type 6 and 11. HPV has its viral factors that exist to avoid immune surveillance and control through 1) infecting only the basal layer of the epithelium, 2) downregulation of host immunity, 3) suppression of proinflammatory proteins essential for viral clearance. The incidence of BLT/GCA is estimated to be 0.1% in the general population, with males having 2.7 times increased

risk than females. BLT/GCA is characterized by verrucous tumor or palpable cauliflower-like mass, exophytic growth, flesh-colored, and uneven surface. The definitive diagnosis of BLT/GCA is typical morphology along with histopathological examination, and/or viral serotyping. Treatment of BLT/GCA requires a multidisciplinary approach, determined based on age, the extent of the lesion, organ involvement, and organ location.

**Keywords:** Buschke Löwenstein tumor, giant condyloma acuminatum, immunology, HPV

**Cite this Article:** Christopher, P.M., Kosim, H., Wijaya, R.S., Suhardi, S., Julianti, L. 2020. Buschke Löwenstein tumor (BLT)/giant condyloma acuminatum (GCA): An immunopathogenesis insight. *Bali Dermatology and Venereology Journal* 3(1): 1-8. DOI: [10.15562/bdv.v3i1.27](https://doi.org/10.15562/bdv.v3i1.27)

<sup>1</sup>Faculty of Medicine, Universitas Pelita Harapan, Tangerang, Indonesia

<sup>2</sup>Department of Dermatovenereology, Universitas Tarumanagara, Indonesia

## INTRODUCTION

Buschke Löwenstein tumor (BLT)/giant condyloma acuminatum (GCA) is a sizeable fungating lesion, with the characteristic of being locally aggressive behavior and low metastatic potential form of condyloma acuminatum (CA) arising in the anogenital region.<sup>1</sup> History of BLT/GCA started in 1896 with the finding by Abraham Buschke and Lowenstein Ludwig when they found a lesion in penile area mimicking CA and squamous cell carcinoma (SCC) with a different biological and histopathological characteristics.<sup>2</sup> BLT/GCA is correlated with sexually transmitted infection (STI) due to human papillomavirus (HPV), which came from the *Papovaviridae* family.<sup>2,3</sup>

Globally, it is estimated that 630 million individuals are infected with HPV, where 30 million genital HPV infections were diagnosed annually.<sup>4</sup> In young adult populations, the cumulative incidence of HPV infected was as high as 40%, with prevalence reaching 75-80%.<sup>5</sup> The highest prevalence and risk of HPV genital infection were found in adolescents, although no significant reduction was found with age progression in Asia and Africa.<sup>6</sup> In Indonesia, based on data from 12 teaching hospitals during the period 2007-2011, CA ranked as one of the top 3 for STI.<sup>7</sup> Nevertheless, case findings for BLT/GCA are relatively rare due to the predisposing factor for the disease in which it happened in individuals in

an immunocompromised state.<sup>8</sup> In addition to the immunocompromised state, a recent finding of HPV's ability to evade immune surveillance, such as causing DNA methylation disturbance to alter gene expression (promoter of CXCL14), has been reported to disrupt the orchestrated attraction of other immune cells. This finding further increases awareness, suspicion, and vigilance when trying to diagnose papillomatous lesions with a verrucous surface in the anogenital region.<sup>9</sup>

The diagnostic approach is based on clinical and further workup examinations in the hope for diagnosis confirmation, shortening the time required for treatment initiation, and yielded better prognosis. The therapeutic modality for BLT/GCA varied amongst physical modality, topical, and immunotherapy.<sup>10</sup> Nevertheless, no gold standard for treatment has been established for BLT/GCA. The objective of this review is to summarise current knowledge about definition and etiology, virology, clinical manifestation, diagnosis and differential diagnosis, management, and prognosis of BLT/GCA, with a specific insight in the immunopathogenesis of HPV.

## Buschke Löwenstein tumor/giant condyloma acuminatum

Buschke Löwenstein tumor (BLT)/giant condyloma acuminatum (GCA) is a rare variant of condyloma acuminatum (CA) characteristically recognized

\*Corresponding author:  
Paulus Mario Christopher;  
Faculty of Medicine, Universitas Pelita Harapan, Tangerang, Indonesia;  
[paulusmarioc@gmail.com](mailto:paulusmarioc@gmail.com)

Received: 2020-01-25  
Accepted: 2020-04-20  
Published: 2020-06-01

with bulky exophytic growth.<sup>1,2</sup> BLT/GCA is often associated with HPV types 6 (66-100% of cases) and 11 (33% cases) characterized by its high recurrence rate and low risk for malignant transformation. In some other BLT/GCA cases, HPV types 1, 4, 16, 18, 31, 33, and 35 were also recognized as the etiological agent.<sup>11</sup>

### Virology

Human papillomavirus (HPV) is a small, 50-60 nm in diameter, nonenveloped, double-stranded deoxyribonucleic acid (DNA) virus with lifecycle and great diversity towards epithelial tropisms. These viridae have icosahedral structure, composed of 72 capsomers, ~8000 base pairs, and encodes eight or nine open reading frames (ORFs). Although the gene number is confined to the small size of the papillomavirus genome, the number of the encoded protein is much higher in which the gene expression involves the use of multiple promoters and intricate patterns of splicing.<sup>12</sup>

The genome of HPV can be divided into three functional sections; 1) early region (E) consisting of E1, E2, E4, E5, E6, and E7, 2) late region (L) consisting of L1 and L2 gene, and 3) long control region (LCR) or upstream regulatory region (URR). E region encoded the protein associated with viral pathogenicity and L region encoded capsid proteins, while the LCR contains the viral *cis*-acting regulatory sequences that regulated viral replication, transcription, and post-transcriptional control via the late regulatory element (LRE).<sup>13-15</sup>

From the host molecular perspective, HPV can gain initial entry into the epithelial cells through a wound or other epithelial trauma. Initial HPV infection at the site of injury of the proliferating basal cells induces basal cell migration and augment cell division, subsequently increasing the likelihood of a productive infection. For the low-risk HPV (LR-HPV) types (e.g., HPV types 6 or 11), the basal stem cell infection may be required at the initial entry site.<sup>12,15</sup> Basal cells have extracellular structural matrix components, namely heparan sulfate proteoglycans (HSPGs), specifically the syndecan-1 (an isotype of HSPG expressed predominantly) together with  $\alpha$ 6-integrin and laminin-5 which facilitate the initial attachment and promotion of conformational changes in viral capsid (L1). Three modes of viral entry have been evident: 1) clathrin-mediated endocytosis, 2) caveolar endocytosis, and 3) clathrin- and caveolae-independent pathway involving tetraspanin-enriched microdomains. Upon basal cell division, an infected daughter cell begins the continuous process of keratinocyte differentiation which triggers a tightly orchestrated step of viral gene expression resulting in a

productive infection.<sup>12</sup>

Principally, for the establishment of HPV infection, the interaction between the host cell cycle and the life cycle of HPV types is essential. A review of the literature undertaken found that, in HPV infection, E6 proteins inactivate p53 function. It was found that LR-HPV types may interfere with p53 function by mediating its cytoplasmic sequestration in contrast to only high-risk HPV (HR-HPV) types (e.g., HPV types 16 and 18), which are able to stimulate p53 proteasome-dependent degradation and ubiquitination. Furthermore, the LR-HPV types also differ from HR-HPV types in that amplification of the genome necessitates the re-entry of the cell cycle in the suprabasal layers of the epithelium rather than occurring in cells that have remained in cycle after division. LR-HPV types' different abilities support this concept compared to HR-HPV types concerning the retinoblastoma protein (pRb), in which LR-HPV can only effectively target the p130 retinoblastoma family member, which controls the cycle of suprabasal, but not basal cells. These explanations may encompass the mechanisms of the types of LR-HPV causing papillomatosis.<sup>12</sup>

### Immunopathogenesis

Host immune responses towards HPV are based on two fundamentals, the innate and the adaptive immunity.

#### *Innate immunity*

The innate immunity is the first line of defense with non-specific characteristics towards pathogens consisting of the epithelial lining, complement system, and immune cells which play roles in phagocytosis, antigen presentation, and pathogen elimination.<sup>16</sup>

#### 1. Keratinocytes

Keratinocytes (KCs) are the pivotal cells of the epidermis and form the intermediate filament keratins that, among other roles, cater structural resiliency to cells, also providing a barrier between the surrounding environment and other tissues of the body.<sup>17</sup> Although KCs are the target of HPV infection, KCs also served as the first line of defense from HPV infection. KCs express pattern recognition receptors (PRRs), such as toll-like receptors (TLRs), nucleotide-binding oligomerization domain-like receptors (NLRs), retinoic acid-inducible gene I-like receptors (RLRs), and cytosolic DNA sensors for pathogen-associated molecular patterns (PAMPs) recognition.<sup>18</sup> Ligated PRRs result in the activation of inflammatory and proliferative signaling pathways of the

host and subsequent initiation of innate and adaptive immune responses.<sup>16</sup> Additionally, activation of TLRs on keratinocytes results in the production of antiviral type I interferons and proinflammatory cytokines that regulate the activation, polarization, and proliferation of innate and adaptive immune cells. Previous study in this area has shown the crucial role of TLRs (TLR3, TLR7, TLR8, and TLR9) for eliminating HPV infection.<sup>18,19</sup>

However, HPV infection has a non-lytic characteristic that serves as one of the principal mechanisms of HPV in evading the immune responses.<sup>9</sup> Viral gene expressions (E6 and E7 protein) interfere with a variety of host immune response to support their persistence through several following mechanisms; (1) downregulation of TLR9 transcription and function, (2) decrease activation and effector response of cytotoxic CD8 T cells by inhibition of the expression of Major Histocompatibility Complex (MHC) class I, (3) interference with the production of cytokines, chemokines, and interferon.<sup>6,13,20</sup>

## 2. Dendritic cells

Dendritic cells (DCs) are professional antigen presenting cells (APCs) that efficiently uptake, process, and present antigen via MHC molecules to T lymphocyte.<sup>16</sup> Langerhans's cells (LCs), a subtype of DCs, are the only antigen presenting cells located in the epidermis where HPV infection occurs.<sup>16</sup> However, HPV is able to escape from LCs immune response via the expression of E6 and E7 protein that may alter the frequency, distribution, and maturation of LCs.<sup>18,20</sup> This is further supported by low CCL20 chemokine production and the reduced expression E-cadherin by KCs (CCL20 is required in the migration process of immature LCs in the epidermis, whereas the E-cadherin play an integral role for the interaction of LCs and KCs, leading to LCs differentiation).<sup>21</sup> In the previous study, it was hypothesized that the lack of LC frequency in cervical samples could lead to a more permissive microenvironment for initiating HPV infection and establishing an infection within the regional tissue, as well as a likely inhibition of effective activation and T-cell recruitment towards cervical mucosa.<sup>22</sup>

Significant reduction in the expression of MHC class II and co-stimulatory molecules on mature LCs (essential for activation of T lymphocytes) occurred in the presence of HPV proteins (E6, E7, L1, and L2). In addition, decreased level of stimulatory cytokines to LCs, such as tumor necrosis factor (TNF)- $\alpha$  and

**granulocyte-macrophage colony-stimulating factor (GM-CSF)**, and the increased level of immunosuppressive cytokines such as IL-10 contribute to further impairment of LCs that occurred during HPV infection.<sup>21,23</sup>

The expression of programmed death-ligand 1 (PD-L1), which interacts with programmed cell death 1 (PD-1) proteins to promote T cell anergy, has been found to be higher in DCs of HR-HPV positive patient comparatively to HR-HPV negative patient.<sup>18,19</sup> In addition, virion production (a highly immunogenic structure) occurs in an immune-privileged apical layer of epithelial lacking LCs surveillance.<sup>9</sup> Overall, the microenvironmental disturbance and the ineffective immune response could be an HPV immune escape mechanism and support their epithelial persistence.

## 3. Natural killer cells

Natural killer (NK) cells are instrumental in mediating antiviral immune response and tumor immunosurveillance. NK cells can recognize and kill virally-infected and transformed cells through three mechanisms; 1) granule-dependent cytotoxicity, 2) death receptor-mediated apoptosis pathways, 3) production of antiviral cytokines, such as interferon (IFN)- $\gamma$ . The activation of NK cells depends on the balance signals of activating and inhibitory receptors.<sup>24,25</sup> NK cells have extraordinary viral efficacy that specifically down-regulates MHC molecules to evade cytotoxic T lymphocytes cells (CTLs) surveillance. Three hypotheses have been proposed for NK cell recognition: 1) loss of self-recognition, 2) stress-induced self-recognition, and 3) non-self-recognition. Loss of self-recognition refers to NK cells activation proceeding a condition when the MHC molecules are low in expression, stress-induced self-recognition refers to some activating receptors recognizing their respective ligands on infected or transformed cells, and non-self-recognition refers to activating receptors that do not recognize endogenous ligands but interact with foreign pathogen encoding proteins.<sup>26</sup>

Cytokines interaction network played a role in activating and differentiating NK, as such IL-12 is a potent inducer of NK cell differentiation and IFN- $\gamma$  production. Nonetheless, the presence of HPV E6 protein capable of inducing high IL-10 expression triggers transcription inhibition of IFN- $\gamma$  and IL-12. Furthermore, the expression of HPV E7 protein can block the JAK-STAT signaling pathway and disrupt the response of NK cells to IFN- $\alpha$ , an essential cytokine for NK

activation and cytolytic activity against viral infection.<sup>25,26</sup>

#### 4. Macrophages

Macrophages are cells derived from monocyte and found in tissues. Macrophages recognize the viral components through TLRs and able to produce several inflammatory cytokines and chemokines in mediating host immune response.<sup>16</sup> Specific proteins, such as macrophage inflammatory protein (MIP)-3 $\alpha$  and monocyte chemotactic protein-1 (MCP-1), whose role is to assist in the aggregation and the chemotaxis of macrophages, appeared to be directly or indirectly down-regulated by HPV E6 and E7 protein. This mechanism prevents the translocation of macrophages to the HPV infection.<sup>21,27</sup>

Tumor-associated macrophages (TAMs) have shown its ability to promote tumor development and progression. Evidence from previous studies revealed that there was a positive correlation between the M2-polarized TAMs and HPV-related cervical carcinogenesis.<sup>28,29</sup> They are capable of promoting cancer cell proliferation and migration, angiogenesis and immunosuppression through; 1) promoting T-helper (Th)2 cells response through IL-4, IL-10, and IL-13, 2) promoting differentiation of naïve T cells into T-regulatory (Treg) cells via IL-10 production, 3) secretion of vascular endothelial growth factor (VEGF) and other proangiogenic factors.<sup>27,30</sup>

#### 5. Natural killer T cells

Natural killer T (NKT) cells are distinct lymphocyte lines distinct from traditional T cells since their receptor recognizes lipid,  $\alpha$ -galactosylceramide ( $\alpha$ GalCer), and is restricted by a non-classical class-I like MHC molecule CD1d.<sup>31</sup> Intracellular signaling mediated by surface CD1d utilizes NF- $\kappa$ B as well as CD1d-recruited NKT cells rapidly produce large amounts of Th1 and Th2 cytokines, including IFN- $\gamma$ , IL-2, IL-4, IL-10, IL-13, IL-17, IL-21, and IL-22, TNF- $\alpha$ , and GM-CSF giving rise to protection against viral infections and cancers and polarization of Th1/Th2. NKT cells specifically stimulate DCs through the CD1d-T cell receptor (TCR) complex and CD40-CD40L interaction, which triggers DC maturation and IL-12 secretion. Thus, CD1d and CD1d-restricted NKT cells serve as a natural bridge between innate and adaptive immune responses to microbes.<sup>19,32</sup> Nonetheless, while CD1d expression is reported to be upregulated by inflammatory cytokines,

during HPV infection, CD1d is found to be downregulated in HPV-related lesions and cancer cell lines by HPV E5 protein.<sup>19</sup> In a previous study, it was demonstrated that systemic NKT cells have a broad immunosuppressive function in response to skin-derived viral antigen, suppressing immunity of CD8 T cells in the priming phase in secondary lymphoid organ and the effector response at the local site, thereby restricting the capacity for successful priming of adaptive immunity.

#### *Adaptive immunity*

Adaptive immunity consists of T- and B cells. T cells population is divided into T-helper cells, cytotoxic T lymphocytes cells, and T regulatory cells. Activation of the innate immune cells contributes to the proliferation and differentiation of cells that further participate in adaptive immune response.<sup>16</sup> Cytokine microenvironment milieu disruptions, such as proinflammatory cytokines under-secretion will dampen the immune response of LCs, macrophages, and recruitment of effector T cells. Subsequently, it reduced the adaptive immune responses to the local injury or infection.<sup>18,34</sup> This evidence is mainly supported in a study showing KCs containing episomal copies of HR-HPV display a large number of deregulated genes involved in chemotactic and proinflammatory mechanisms.<sup>24</sup>

#### 1. T Cells

For the active clearance of HPV infection, robust Th cells and CTLs responses are required. This mechanism is focused on the induction of the innate immune system, especially for CD4+ T cells, because they are an integral component for effective cellular and humoral (antibody) host immune defenses. The local microenvironment cytokine influences CD4+ T cells' response for phenotype switching between Th1 or Th2 cells. Th1 promotes cell-mediated immune response and Th2 induces a humoral immune response. In women with HPV infections, which develop into high-grade lesions, the immune response's polarization to the Th2 cell pattern was observed. This fundamental polarization describes a deficit in the cellular immune response to HPV and neoplasia, as the deviation towards Th2 induces a humoral response and inhibits cellular response.<sup>20</sup>

Cytotoxic T lymphocyte cells are an essential effector component of Th1 immune responses and can kill virally infected cells. In theory, CTLs are targeted against E6 and E7, allowing it to kill even basal cells infected with HPV in the early viral replication phase. Nonetheless,

HPV can suppress the CTL response by down-regulating the transporter associated with antigen protein (TAP1), resulting in antigen presentation cycle impairment. Reduced HPV peptide presentation by MHC class I inhibits the recruitment of specific HPV CTLs and the entry of infected cells by effector CTLs.<sup>20</sup> Another mechanism for HPV evasion is the integration of the HR-HPV DNA into the cellular genome that occurred near the *c-myc* gene, resulting in this gene being over-expressed leading to diminished expression of the human leukocyte antigen (HLA)-A and B genes.<sup>34</sup>

On the contrary, T-regulatory cells are essential in the viral clearance failure and suppression of anti-tumor immune responses. In a previous study, the increase of Treg cells and immunosuppressive cytokines was significantly associated with the severity of the lesions and high viral loads, suggesting that T-regulatory cells contribute to viral persistence and progression of neoplasia.<sup>35</sup> HPV infection may viral-specific Tregs development. This antigen-experienced Tregs impairs the maturation of DCs through CTLA-4 (CTLA-4). Therefore, it exerts detrimental immunomodulatory effects on the innate and adaptive immunity.<sup>36</sup>

## 2. B cells

The growth and maturation of B cells, the lymphocytes in-charge for antibodies production, depends on the interaction with APCs and cytokine profile released from Th cells. Antibodies functionality was developed

to neutralize and opsonize foreign antigen for killing as well as to prevent infection from susceptible host cells. Antibodies formed during natural infection are targeted at E2, E6, E7, L1, and L2. Specifically, there are two distinct classes of antibodies that have L1 binding characteristics; monoclonal antibodies may either 1) prevent extracellular matrix bonding but not the epithelial cells or 2) prevent epithelial cells bonding but not extracellular matrix bonding.<sup>20</sup> Nevertheless, in a recent study, the generation of the immune response of neutralizing antibodies to L1 is slow where the average seroconversion is between 8 and 9 months after the first HPV DNA detection, the antibody titers are low, and only between 50 and 70 percent of women seroconvert.<sup>37</sup>

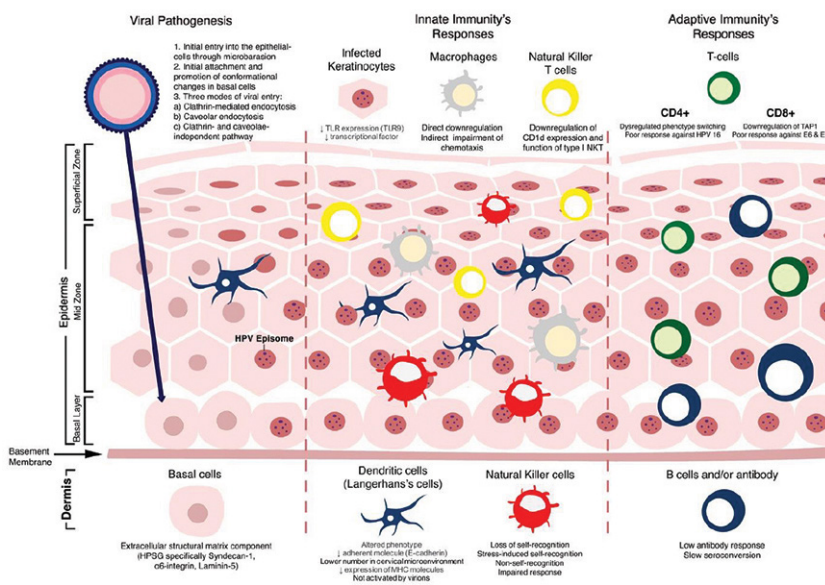
The host immune system's principal role, specifically the adaptive immunity, was explained by various events in the progression of HPV infection.<sup>38</sup> About 2/3 immunocompetent individual groups infected with HPV experienced a transient infection due to the host immune system's ability to eliminate the virus infection.<sup>39</sup> Immunosuppression is considered to be a predisposing factor for HPV infection, where HPV prevalence and persistence of infection increase accordingly with the degree of the immunodeficiency and are found in patients with an immunosuppressed condition such as kidney transplant patients receiving immunosuppressive therapy, Hodgkin lymphoma, and patients with human immunodeficiency virus (HIV).<sup>40-42</sup>

## Clinical manifestations

Clinical manifestations of BLT/GCA are characterized by verrucous tumor or palpable cauliflower-like mass, with varying sizes, exophytic growth, flesh-colored, and uneven surface. This mass can be associated with or without pain, suppurating signs/fistula formation, and ulceration in the anogenital region.<sup>1,43</sup>

## Diagnosis

Diagnosis of BLT/GCA will be made based on history taking, physical examination, and/or supportive examinations. History taking consisted of question concerning the growth of the lesion, past medical history such as 1) diabetes mellitus, 2) hypertension, 3) dyslipidemia, 4) hypothyroid, and/or 5) stroke, sexual history, risk factors concerning 1) smoking history, 2) history of hormonal contraceptive use, 3) multiple sexual partners, 4) age of first sexual initiation and 5) immunodeficient status as in acquired immunodeficiency syndrome (AIDS) or chemotherapy with immunosuppressant(s).<sup>8,44</sup>



**Figure 1.** Human papillomavirus (HPV) pathogenesis and related host-microbe immune interplay

Further workup examinations consisted of histopathological examination, viral serotyping with polymerase chain reaction (PCR), and imaging modalities. The histopathological examination usually reveals stratified squamous epithelial layers with acanthosis, hyperkeratosis, papillomatosis, parakeratosis, orthokeratosis, koilocytes, and without basement membranes involvement nor malignancy transformation sign. Koilocytes are atypical keratinocyte transformation characterized by cell enlargement, eccentric pyknotic nuclei surrounded by a perinuclear halo.<sup>3,45</sup>

Imaging modalities serve its function in determining the extent of the disease and damage to the surrounding tissues to ascertain surgical resection feasibility. Magnetic resonance imaging (MRI) holds its superiority in terms of sensitivity compared to computed tomography (CT) scan.<sup>46</sup>

### Differential diagnosis

Differential diagnosis of BLT/GCA comprised of verrucous carcinoma, warty/warty-basaloid high grade squamous intraepithelial lesion and squamous cell carcinoma (SCC), papillary SCC, bowenoid papulosis, verruca vulgaris, epidermolytic acanthoma, and/or verruciform xanthoma.<sup>47</sup>

### Management

First-line/gold standard treatment regarding BLT/GCA has not yet been established due to its rarity, resulting in a lack of reproducible studies. Nevertheless, it has been found through researches that management of BLT/GCA is divided into three types: 1) tumor removal or physical modalities (including surgical excision or cryotherapy using liquid nitrogen, CO<sub>2</sub> laser therapy, electrosurgery) 2) topical (including podophyllin, fluorouracil [5-FU], bleomycin, interferon) or radiotherapy, and 3) immunotherapy including imiquimod.<sup>2,10,48</sup> All these modalities have their varying success rate and yet been set as the gold standard management of BLT/GCA. Notable considerations in managing the case are each modality's success rate based on size and the metastasis rate of BLT/GCA itself.

### Prognosis and prevention

Although BLT/GCA has its probability of recurrence, with early detection, periodic follow up (timeline for follow up has not been established yet), and early management, this disease holds a significant recovery. Morbidity of BLT/GCA is mainly due to the lesion characteristic of being locally invasive, bleeding, infection, recurrence, and perioperative complication while mortality of BLT/GCA is due to malignant transformation in both male and female population.<sup>1,48,49</sup> Prevention of this disease can be achieved through HPV vaccination

as well as adequate early management of CA to prevent potential growth from this disease.<sup>15,27,50</sup>

## CONCLUSION

Buschke Löwenstein tumor (BLT)/giant condyloma acuminatum (GCA) is a rare type of human papillomavirus (HPV) infection affecting the anogenital region. HPV infection has its distinctive features and the natural host immune response, which affects the virus' natural course. While the innate or cell-mediated immune responses may be ideally suited to fight infection after viral entry into epithelial cells, CD4+ T-cell immunity and high concentrations of neutralizing antibodies may provide a significant advantage in preventing initial infection. The holistic approach needs to be taken into consideration to ensure a proper diagnosis and treatment plan.

## AUTHORS CONTRIBUTION

All authors contributed to the reference search, manuscript preparation, and publication.

## CONFLICT OF INTEREST

The authors declared no conflict of interest regarding publication.

## FUNDING

None.

## REFERENCES

- Martín JM, Molina I, Monteagudo C, Marti N, López V, Jorda E. Buschke-Lowenstein tumor. *J Dermatol Case Rep.* 2008; 4: 60-2.
- Safi F, Bekdache O, Al-Salam S, Alashari M, Mazen T, El-Salhat H. Management of peri-anal giant condyloma acuminatum – A case report and literature review. *Asian J Surg.* 2013; 36(1): 43-52.
- Yanofsky VR, Patel RV, Goldenberg G. Genital warts a comprehensive review. *J Clin Aesthet Dermatol.* 2012; 5(6): 25-36.
- Manga MM, Fowotade A, Yahaya M. Human papillomavirus (HPV) infection in males: A need for more awareness. In: *Current perspectives in human papillomavirus.* InTechOpen; 2019. p. 4.
- Shew ML, Fortenberry JD. HPV infection in adolescents: Natural history, complications, and indicators for viral typing. *Semin Pediatr Infect Dis.* 2005; 16(3): 168-74.
- Saxena SK, Kumar S, Goel MM, Kaur A, Bhatt MLB. Recent advances in human papillomavirus infection and management. In: *Current perspectives in human papillomavirus.* InTechOpen; 2019. p. 2.
- Niode NJ. Infeksi saluran reproduksi dan infeksi menular seksual di poliklinik kulit dan kelamin RSUP Prof. DR. R. D. Kandou, Manado. *MDVI.* 2016; 43(3): 84-8.
- Martínez-Cumplido R, Gonzalez-Bosquet E. Giant cervical condyloma during pregnancy: A case report. *Int J Women's Health Reprod. Sci.* 2016; 4(2): 81-3.

9. Steinbach A, Riemer AB. Immune evasion mechanisms of human papillomavirus: An update. *Int J Cancer*. 2018; 142: 224-29.
10. Niazy F, Rostami K, Motabar AR. Giant condyloma acuminatum of vulva frustrating treatment challenge. *World J Plast Surg*. 2015; 4(2): 159-62.
11. Türkdogan P, Bastürk O, Demir MA, Zeytinoglu A, Seyhan A. Giant condyloma acuminatum – Two cases with microinvasive foci in one. *Aegean Pathology Journal*. 2004; 1: 62-5.
12. Doorbar J, Egawa N, Griffin H, Kranjec C, Murakami I. Human papillomavirus molecular biology and disease association. *Rev Med Virol*. 2016; 25: 2-23.
13. Miller DL, Puricelli MD, Stack MS. Virology and molecular pathogenesis of HPV (human papillomavirus) – Associated oropharyngeal squamous cell carcinoma. *Biochem J*. 2012; 443 (2): 339-53.
14. Georgescu SR, Mitran CI, Mitran MI, et al. New insights in the pathogenesis of HPV infection and associated carcinogenic processes: The role of chronic inflammation and oxidative stress. *J Immunol Res*. 2018; 2018: 1-10.
15. Graham S V. The human papillomavirus replication cycle, and its links to cancer progression: A comprehensive review. *Clin Sci*. 2017; 131(17): 2201-21.
16. Abbas AK, Lichtman AH. Basic immunology functions and disorders of the immune system. 3rd ed. Philadelphia: Elsevier; 2011.
17. Garza L. Developmental biology of the skin. In: Kang S, Amagai M, Bruckner AL, Enk AH, Margolis DJ, et al, editors. *Fitzpatrick's dermatology*. New York: Mc Graw Hill Education; 2019. p. 49.
18. Nunes RAL, Morale MG, Silva GAF, Villa LL, Termini L. Innate immunity and HPV: friends or foes. *Clinics*. 2008; 73(1): e549s.
19. Sasagawa T, Takagi H, Makinoda S. Immune responses against human papillomavirus (HPV) infection and evasion of host defense in cervical cancer. *J Infect Chemother*. 2012; 18: 807-15.
20. Einstein MH, Schiller JT, Viscidi RP, et al. Clinician's guide to human papillomavirus immunology: knowns and unknowns. *Lancet Infect Dis*. 2009; 9(6): 347-56.
21. Wakabayashi R, Nakahama Y, Nguyen V, Espinoza JL. The host-microbe interplay in human papillomavirus-induced carcinogenesis. *Microorganisms*. 2009; 7(199): 1-22.
22. Jimenez-Flores R, Mendez-Cruz R, Ojeda-Ortiz J, Muñoz-Molina R, Balderas-Carrillo O, De La Luz Diaz-Soberanes M, et al. High-risk human papilloma virus infection decreases the frequency of dendritic Langerhans' cells in the human female genital tract. *Immunology*. 2006;117(2):220-8.
23. Camargos DDS, Tafuri A, Fernandes PA, Caliani MV, Dutra WO, Vago AR. Langerhans cells ascertaining in cervical tissues obtained from women with cervical intraepithelial neoplasia. *Reprod Syst Sex Discord*. 2017; 6(1): 1-5.
24. Sutlu T, Alici E. Natural killer cell-based immunotherapy in cancer: Current insights and future prospects. *J Intern Med*. 2009;266(2):154-81.
25. Utami TW. NK-Cell Count and its Function in Producing Interferon Gamma Associated with the Cervical Cancer Natural History. *Glob J Reprod Med*. 2018;4(2):1-6.
26. Zhao H, Zhang J-X. Natural killer cells: the first defense against human papilloma virus early infection. *J Public Heal Emerg*. 2017; 1(5): 5-5.
27. Deligeoroglou E, Giannouli A, Athanasopoulos N, Karantzou V, Vatopoulou A, Dimopoulos K, et al. HPV infection: Immunological aspects and their utility in future therapy. *Infect Dis Obstet Gynecol*. 2013; 2013: 1-9.
28. Chen XJ, Han LF, Wu XG, Wei WF, Wu LF, Yi HY, et al. Clinical significance of CD163+ and CD68+ tumor-associated macrophages in high-risk HPV-related cervical cancer. *J Cancer*. 2017; 8(18): 3868-75.
29. Zhou C, Tuong ZK, Frazer IH. Papillomavirus Immune Evasion Strategies Target the Infected Cell and the Local Immune System. *Front Oncol*. 2019; 9: 1-18.
30. Barros MR, de Melo CML, Barros MLCMGR, de Cássia de Lima R, de Freitas AC, Venuti A. Activities of stromal and immune cells in HPV-related cancers. *J Exp Clin Cancer Res*. 2018; 37(137): 1-18.
31. Terabe M, Berzofsky JA. Tissue-specific roles of NKT cells in tumor immunity. *Front Immunol*. 2018; 9: 1-11.
32. Roberson FC, Berzofsky JA, Terabe M. NKT cell networks in the regulation of tumor immunity. *Front Immunol*. 2014; 5: 1-13.
33. Stanley MA, Sterling JC. Host responses to infection with human papillomavirus. *Curr Probl Dermatol*. 2014; 45: 58-74.
34. Gonçalves MAG, Donadi EA. Immune cellular response to HPV: current concepts. *Braz J Infect Dis*. 2004; 8(1): 1-9.
35. Bonin CM, Padovani CTJ, da Costa IP, et al. Detection of regulatory T cell phenotypic markers and cytokines in patients with human papillomavirus infection. *J Med Virol*. 2018; 91(2): 317-25.
36. Ao C, Zeng K. The role of regulatory T cells in pathogenesis and therapy of human papillomavirus-related diseases, especially in cancer. *Infect Genet Evol*. 2018; 65: 406-13.
37. Gutierrez-Xicotencati L, Salazar-Piña DA, Pedroza-Saavedra A, Chihu-Amparan L, Rodriguez-Ocampo AN, Maldonado-Gama M, Esquivel-Guadarrama FR. Humoral immune response against human papillomavirus as source of biomarkers for the prediction and detection of cervical cancer. *Viral Immunol*. 2016; 29(2): 1-12.
38. Yunihastuti E. Infeksi HPV pada HIV. In: Adrijono, Indriatmi W, editors. *Infeksi human papillomavirus*. Jakarta: Badan Penerbit Fakultas Kedokteran Universitas Indonesia; 2013. p. 183-6.
39. Mayeaux EJ, Dunton C. Modern management of external genital warts. *J Low Genit Tract Dis*. 2008; 12(3): 185-92.
40. Cistjakovs M, Sultanova A, Jermakova O, et al. Importance of High-Risk Human Papillomavirus Infection Detection in Female Renal Transplant Recipients in the First Year after Transplantation. *Infect Dis Obstet Gynecol*. 2018; 2018: 1-8.
41. Intaraphet S, Farkas DK, Schmidt SAJ, Cronin-Fenton D, Søgaard M. Human papillomavirus infection and lymphoma incidence using cervical conization as a surrogate marker: A Danish nationwide cohort study. *Hemato Oncol*. 2015; 35(2): 172-6.
42. Palefsky J. Human papillomavirus-related disease in people with HIV. *Curr Opin HIV AIDS*. 2009; 4(1): 52-6.
43. Reyes JFR, Rocha JAS, Gonzalez OCL, Varea JAH, Rodriguez PRL. Giant Cumulated Condyloma (Tumor of Buschke Löwenstein) Presentation of a Case. *J Surg Open Access*. 2019; 5(3): 1-4.
44. Hum M, Chow E, Schuurmans N, Dytoc M. Case of giant vulvar condyloma acuminatum successfully treated with imiquimod 3.75% cream: A case report. *SAGE Open Med Case Reports*. 2018; 6: 1-5.
45. Sandhu R, Min Z, Bhanot N. A gigantic anogenital lesion: Buschke-Lowenstein tumor. *Case Rep Dermatol Med*. 2014; 2014: 1-3.
46. Montaña N, Labra A, Schiappacasse G. Giant condyloma acuminatum (Buschke-Lowenstein tumor). Series of seven cases and review of the literature. *Rev Chil Radiol*. 2014; 20(2): 57-63.
47. Chan MP. Verruciform and condyloma-like squamous proliferations in the anogenital region. *Arch Pathol Lab Med*. 2019; 143: 821-31.

48. Pineda-Murillo J, Lugo-García JA, Martínez-Carrillo G, Torres-Aguilar J, Viveros-Contreras C, Schettino-Peredo MV. Buschke-Löwenstein tumor of the penis. *Afr J Urol*. 2019; 25(9): 1-4.
49. Purzycka-Bohdan D, Szczerkowska-Dobosz A, Swiatecka-Czaj J, Peksa R, Urban M, Szcypior M, Nowicki RJ. Buschke-Löwenstein tumour associated with low-risk human papillomavirus genotypes successfully treated surgically. *Adv Dermatol Allergol*. 2019; 36(1): 112-4.
50. Ahmed SMR, Islam MS, Ali SMY, Akhtar N, Hasan MS. Giant condyloma acuminatum of vulva. *Bangabandhu Sheikh Mujib Med Univ J*. 2017; 10: 169-72.



This work is licensed under a Creative Commons Attribution