

## Systematic review of melasma treatments: advantages and disadvantages



Sang Ayu Arta Suryantari<sup>1\*</sup>, Ni Putu Tamara Bidari Sweta<sup>1</sup>, Elvina Veronica<sup>1</sup>,  
I Gusti Ngurah Bagus Rai Mulya Hartawan<sup>1</sup>, Ni Luh Putu Ratih Vibriyanti Karna<sup>2</sup>

### ABSTRACT

**Background:** Melasma is acquired chronic hyperpigmentation mainly affecting women. The pathogenesis of melasma is uncertain, but it is predominantly related to ultraviolet (UV) exposure. Due to its chronic and relapsing nature, melasma is challenging to treat. The currently available treatment often has undesirable side effects and suboptimal results. The treatment principle includes protecting from UV radiation, inhibiting melanin synthesis, and increasing the pathway to remove melanin.

**Objectives:** To define available treatments for melasma and determine advantages and disadvantages, including topical, oral and procedural.

**Method:** Medline, Cochrane library and PubMed databases were searched for articles from January 2011 to June 2020. Only RCTs, comparative, prospective, retrospective and systematic reviews focusing on melasma treatments were extracted, analyzed and discussed.

**Results:** We found 197 studies that met the inclusion and exclusion

criteria, with 2314 participants included in this review. The treatments included topical, oral and procedural. In several studies, hydroquinone alone or combination remains the most effective treatment for melasma. Oral and topical tranexamic acid is a beneficial adjuvant treatment in refractory melasma with minimal adverse effects. Procedural treatments such as chemical peels, laser and light-based therapies, and microneedling have mixed and unpredictable results. Overall, the side effects tend to be mild and affect a few of the subjects.

**Conclusions:** The current state of the evidence suggests that some treatments with multiple modalities have their respective advantages and disadvantages. The choice of treatment modality must be adjusted according to the type of melasma, such as its severity, extent and location. A better understanding of melasma through further research may improve the therapy options with the least adverse effects.

**Keywords:** Melasma, treatment, advantages, disadvantages

**Cite this Article:** Suryantari, S.A.A., Sweta, N.P.T.B., Veronica, E., Hartawan, I.G.N.B.R.M., Karna, N.L.P.R.V. Systematic review of melasma treatments: advantages and disadvantages. *Bali Dermatology and Venereology Journal* 3(2): 37-51. DOI: [10.15562/bdv.v3i2.41](https://doi.org/10.15562/bdv.v3i2.41)

<sup>1</sup>Faculty of Medicine, Universitas Udayana, Bali, Indonesia

<sup>2</sup>Departement of Dermatology and Venerology, Sanglah Hospital, Bali, Indonesia

\*Corresponding author:  
Sang Ayu Arta Suryantari;  
Faculty of Medicine, Universitas Udayana, Bali, Indonesia;  
[sangayu.suryantari@student.unud.ac.id](mailto:sangayu.suryantari@student.unud.ac.id)

Received: 2020-09-24  
Accepted: 2020-11-26  
Published: 2020-12-15

### INTRODUCTION

Melasma or chloasma is a common acquired dermatological condition that primarily affects the woman. This condition describes clinically as chronic and relapsing irregular macules or patches hyperpigmentation that occurs commonly on the face, predominantly attributed to UV exposure. UV radiation induces oxidative stress, which stimulates the melanocyte to synthesis melanin. While melasma does not present any health risk, it can cause significant psychological impact to many patients.<sup>1,2</sup>

The pathogenesis of melasma remains unknown, but multiple factors including UV exposure, genetic factor, inflammation and female sex hormones have been implicated and reviewed.<sup>3</sup> Melasma is classified according to clinical and histological features. Three common type melasma on face are centrofacial, malar, and mandibular. Extra-facial melasma can

occur in the neck, sternum, and upper extremities. Based on pigment location, it may be epidermal, dermal or mixed.<sup>3,4</sup> This classification is important to define treatment options and prognosis.

Treatment of melasma generally starts with management risk factors, UV protection and clearing of the lesion with the fewest possible adverse effects. The principles of therapy include inhibition synthesis melanin pathway, a decrease of melanosome transfer from melanocytes to keratinocytes, and acceleration melanin remove pathway.<sup>5</sup> This research was to define available treatments for melasma and determine advantages and disadvantages, including topical, oral and procedural.

### METHODS

The data search on Medline, Cochrane library and PubMed for articles published from January

2011 to June 2020 using keywords 'melasma' OR 'chloasma' AND 'treatment' AND 'meta analyzes' OR 'RCT' OR 'comparative' OR 'review'. The studies were categorized according to the type of treatment: topical, oral and procedural. Only RCTs, comparative, prospective, retrospective and systematic reviews focusing on melasma treatments in English were extracted, analyzed and discussed. Studies in the community, dermatology clinic and hospital were considered. The resulting measure reviewed includes outcomes, advantages and disadvantages of treatment.

## RESULTS

The online literature search resulted in 197 citations (Figure 1), 42 met inclusion criteria and were included in this review. The total sample size was 2314 subjects, with each study including between 12 to 160 subjects. The time length of each study between 3 to 48 weeks. Thirty-four studies were randomized control trials, three were comparative, 2 were retrospective and 3 were prospective. Below, we review each of these groups of treatment.

### Topical treatments

#### Hydroquinone (HQ)

A topical agent is known as the first-line treatment of melasma. Topical agents in melasma treatment can be used as monotherapy, dual therapy, or triple therapy combination.<sup>6,7</sup> Hydroquinone (HQ) or known as dihydroxy benzene, is one of the topical agents that can inhibit DOPA conversion by tyrosinase enzyme inhibition, affects melanocytes structures and cause necrosis of melanocytes that can inhibit the melanogenesis process.<sup>6-8</sup> It is known that 2-4% HQ cream is effective as melasma treatment, although it still has adverse effects such as irritation, erythema, contact dermatitis and ochronotic.<sup>6,7</sup> Several studies report that many topical agents have better efficacy in

treating melasma compared to HQ, like flutamide, azelaic acid, niacinamide, etc. A double-blind RCT study by Adalatkah and Sadeghi reported that 1% flutamide cream had higher efficacy than 4% HQ cream, although 4% HQ cream had a wider spectrum in treating melasma compared to 1% flutamide cream.<sup>8</sup> Monteiro *et al.* compared 4% HQ and 0.75% kojic acid (KA) in Indian patients, showed that 4% HQ has higher efficacy and faster onset of action than 0.75% KA, but side effects more occurred on HQ group in this study.<sup>9</sup> Yenny and Lestari's study in 2013 showed that 4% arbutin as hydroquinone derivatives cream was safer than hydroquinone cream itself.<sup>10</sup> Double-blind study by Navarrete *et al.* in 2011 with 27 patients was showed that 4% niacinamide was more effective and safer than 4% HQ cream with few patients suffered from mild erythema and burning than 4% HQ cream that had moderate erythema and burning.<sup>11</sup> That's why some studies recommended HQ combination usages with other topical agents to minimize its effect and increase the efficacy effect.

#### Azelaic acid (AZA)

Azelaic acid (AZA) has a cytotoxic effect of inhibiting DNA synthesis and mitochondria enzyme in the melanocyte. Azelaic acid acts as tyrosinase inhibitors, inhibit DNA synthesis of melanoma cell line without resulting dangerous side effect like ochronotic.<sup>6,7</sup> A study by Farshi *et al.* showed that 20% AZA cream is safer than 4% HQ cream, although it has similar side effects such as local irritation like erythema, burning, or itching.<sup>12</sup> Bansal *et al.* in 2012 found that 20% AZA cream was better in treating melasma compared to low-fluence 1064-nm Q-Switched Nd: YAG Laser. The combination of both resulting in better efficacy compared to 20% AZA cream and low-fluence 1064-nm Q-Switched Nd: YAG laser alone as monotherapy.<sup>13</sup>

#### Tranexamic acid (TA)

Tranexamic acid (TA) have first reported in 1979 as melasma treatment. It is an anti-plasmin agent that decreases the generation of arachidonic acid, which leads to a reduction in melanocyte-stimulating hormone (MSH) and a decrease in pigmentary production. A previous study also showed that TA might also decrease endothelin-1 and VEGF that responsible for increasing vascularity in affected lesions.<sup>6,7,16</sup> TA can use as topical and oral therapy. A double-blind study by Ebrahimi *et al.* in 50 Iran patients using 3% topical TA versus combination 3% HQ cream and 0.01% dexamethasone topical cream twice daily for 12 weeks.<sup>14</sup> It showed that TA cream was a higher improvement in melasma

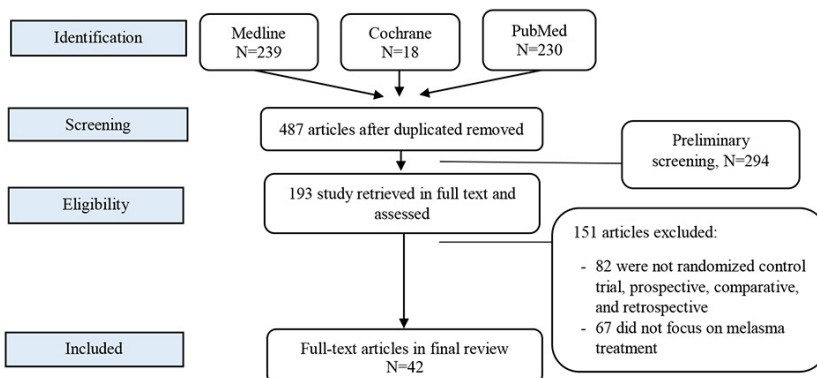


Figure 1. Flow chart study selection process

therapy compared with combined cream based on MASI score, although the difference between MASI score was not significant. Hassal *et al.* study reported that 5% TA cream was more effective than 1% flutamide topical cream without adverse effects were reported.<sup>15</sup> The Janney *et al.* study also showed that TA cream was safer than HQ cream as monotherapy treatment, although it could cause erythema, skin irritation, xerosis, and scaling in long term usage.<sup>16</sup>

#### *Kojid acid (KA)*

Kojid acid (KA) or 5-hydroxy-2-hydroxymethyl-4-pyrone acts by inhibiting the production of free tyrosinase.<sup>17,18</sup> Combination KA and HQ were reported as superior depigmenting agent compared with other combinations. Kojic acid may cause erythema and contact dermatitis. Kojic acid has a better effect when combined with other topical agents. A single-blind RCT study by Deo *et al.* reported that kojic acid more effective in decreased MASI score compared with 2% hydroquinone.<sup>17</sup> It is different from Yenny's study showed 5% methimazole has a higher effect in decreasing MASI score and safer than 4% kojic acid.<sup>18</sup>

#### *Cysteamine*

Cysteamine is an L-cysteine product metabolism that acts as an anti-oxidant and antimutagenic agent. Cysteamine inhibits DNA polymerase, and cell progression that inhibits the melanogenesis process and can be used as alternative melasma treatment topical agents.<sup>19,20</sup> Farshi *et al.* study in 40 Indian patients reported that cysteamine cream was effective to treat melasma based on decreased MASI score compared to placebo.<sup>19</sup> It also reported a small number of adverse effects like 1<sup>st</sup>-grade erythema, itching and 1<sup>st</sup>-grade burning.<sup>19</sup> Similar study in 2015 by Mansouri *et al.* also showed that 5% of cysteamine cream was effective in treating melasma compared to placebo.<sup>20</sup>

#### *Combination topical agents*

Several studies reported the combination between 4% HQ cream and tretinoin cream (either 0.025% or 0.05%).<sup>21-23</sup> Gold *et al.* study in 2013 showed that a combination between 4% HQ cream and 0.05% tretinoin cream could reduce duration therapy compared to monotherapy and increased patients' quality of life significantly at the end of treatment.<sup>21</sup> Similar result was found in Grimes study that combination therapy can reduce the duration of therapy. This study also showed adverse effects such as erythema, burning, or stinging sensation occurred less than in hydroquinone cream or tretinoin cream as monotherapy.<sup>22</sup> Another study

by Ibrahim *et al.* in 2015 found that a combination between 4% HQ and 0.01% hyaluronic acid cream had higher efficacy than placebo and another group. Hyaluronic acid played a role in cell motility via CD44 receptor and increased cell differentiation via the receptor for hyaluronic acid-mediated motility (RHAMM) and increased accelerated epidermal desquamation and quick pigment dispersion. On the other hand, a combination between 4% HQ cream and 10% glycolic acid cream could treat dermal melasma with more severe adverse effects such as mild pruritus, irritant, and erythema compared to another group.<sup>23</sup>

A previous study reported that topical triple combination cream is more effective in treating melasma than monotherapy or dual therapy.<sup>6,7,24-27</sup> Ahmad *et al.* study in 22 Iran women reported that each composition between triple regimen therapy (2% HQ, 0.025% tretinoin, and 1% mometasone) could work synergy, maximized the work of every component and minimalized side effects. Twice weekly application of combination cream for six months was more effective and had a lower relapse in severe melasma.<sup>24</sup> A study by Pekmezci in 68 Turkey female patients found that combination cream between 4% azelaic acid, 0.04% methylprednisolone aceponate, 1.6% HQ, and 2% salicylic acid could decrease duration therapy, synergy work completes each other function and minimalizing the risk of undesirable effects. Irritation or erythema was an adverse effect that might occur.<sup>25</sup> A contrasting result by Fragoso *et al.* found that combination (4% azelaic acid, 0.04% methylprednisolone aceponate, 1.6% HQ, and 2% salicylic acid) had the same effect as 4% HQ in melasma treatment with the adverse effect more occurs than 4% HQ cream.<sup>26</sup>

Based on previous studies, the most recommend formula in triple combination cream is Kligman and Willis formula (5% HQ, 0.1% dexamethasone, and 0.1% tretinoin) because it can decrease MASI score significantly, increase and maximize the efficacy and performance of every topical agent in that combination, shorter duration of treatment, and minimize the side effects of regimen usage.<sup>27</sup> Study by Sardesai *et al.*, in 160 Indian patients with five regimen groups found 70% of patients who used modified Kligman's formula (2% HQ + 0,025% Tretinoin + 0,1% Mometasone furoate) had a better effect in melasma treatment based on significantly decreased of MASI score than another regimen group. Overall, triple combination suggested become the first line and recommended for melasma therapy, although we should be aware of adverse effects and use it no longer than recommendation time.<sup>27</sup> Majid *et al.* study in 2010 found that the usage of triple combination

could treat mild melasma, but if it uses more than recommended duration, it can make melasma worsen than before treatment. It found that 33% of respondents felt their melasma was worsened (they suffered from telangiectasia, acneiform eruption, hypertrichosis) compared with before treatment.<sup>28</sup>

**Table 1.** Topical melasma treatment studies

Author, year, study design	Treatment	N	Advantages	Disadvantages
<b>Monotherapy</b>				
Adalatkah and Sadeghi. <sup>8</sup> (2015) RCT, double-blind	1% flutamide topical cream versus 4% hydroquinone topical cream Duration: 4 months Evaluation: MASI, mexameter melanin assay	74 women	Flutamide has higher efficacy than hydroquinone while hydroquinone has a wide spectrum for melasma topical treatment.	Too much usage of flutamide topical drugs can cause mild systemic adverse effects
Monteiro <i>et al.</i> <sup>9</sup> (2013) RCT, single-blind	4% topical HQ vs. 0.75% KA (Kojid Acid) Duration: 12 weeks Evaluation: MASI	60 Indian patients	4% HQ has higher efficacy and faster onset of action than 0.75% KA. 4% HQ has melanosomes degradation, melanocytes destruction, inhibition of DNA and RNA synthesis.	Side effects (erythema and burning sensation) were noted in one patient (3.3%) receiving 0.75% KA and two patients (6.7%) receiving 4% HQ cream. KA was safer than HQ.
Yenny & Lestari. <sup>10</sup> (2013) RCT, single-blind	Arbutin 4% (hydroquinone derivatives) Duration: 2 months Evaluation: MASI	20 Padang patients	Arbutin is no toxic to melanocytes, safer than hydroquinone, acts as an inhibitor of melanosome tyrosinase activity.	All respondents feel reddish and warm on their face
Navarrete <i>et al.</i> <sup>11</sup> (2011) A comparative study, double-blind	4% niacinamide cream on one side of the face and 4% HQ cream on the other face side Duration: 8 weeks Evaluation: MASI, photography, colorimetric, histopathology by biopsy, chromameter, PGA	27 patients	4% niacinamide was effective in around 40% patient. Niacinamide can be used in long term usage âmast cell infiltrate,â pigmentation, inflammatory infiltrate, and # solar elastosis in melasma skin and safer than 4% HQ cream.	2 (7%) patients suffered from erythema, burning on the niacinamide side, and 18 patients (5%) suffered from that at HQ side and pruritus. Most of them were mild for niacinamide and moderated for HQ.
Farshi. <sup>12</sup> (2011) RCT, double-blind	4% hydroquinone cream (for 15 women) and azelaic acid cream (for 14 patients). Duration: 2 months applied twice daily. Evaluation: MASI	29 Iran women	20% azelaic acid cream more effective than hydroquinone 4% in reducing mild melasma. Azelaic acid acts as a tyrosinase inhibitor inhibits DNA synthesis of melanoma cell line without resulting dangerous side effect like ochronosis	Local irritation more occurs with azelaic acid. Severe adverse effects (pruritus, erythema, irritation) and allergic sensitization more common with hydroquinone cream.
Bansal <i>et al.</i> <sup>13</sup> (2012) RCT, open-label	20% AZA (Azelaic Acid) versus low-fluence 1064-nm Q-Switched Nd: YAG Laser versus combination both of them Duration:12 weeks Evaluation: MASI	60 patients	Better than low-fluence 1064-nm Q-Switched Nd: YAG Laser in melasma treatment	Local irritants (burning, irritants, itching)
Ebrahimi and Fatemi. <sup>14</sup> (2014) RCT, double-blind	Topical solution 3% TA (Tranexamic acid) on one side of the face, and topical solution of 3% hydroquinone + 0.01% dexamethasone on the other side two times a day. Duration: 12 weeks Evaluation: MASI every four weeks, photography at week 12	50 Iran melasma patients	Topical tranexamic acid (TA) safer than oral TA.	Erythema, skin irritation, xerosis, and scaling in long term usage.
Hassan <i>et al.</i> <sup>15</sup> (2018) A comparative study, single-blind	1% flutamide topical on the right side (side A) of the face and 5% tranexamic acid topical on the left side of the face (side B) every night Duration: 12 weeks Evaluation: mMASI	30 Egypt female patients	Topical tranexamic acid is cheaper than laser and more effective than flutamide. Tranexamic acid acts as a plasmin inhibitor, preventing its binding to the lysine-binding site that leading to inhibition of plasminogen activator (PA) from converting plasminogen to plasmin and inhibit bFGF in melanogenesis.	No side effects were reported during this research

Janney <i>et al.</i> <sup>16</sup> (2019) RCT, single-blind	topical 5% TA solution for group A and 3% HQ cream for group B Duration: 12 weeks Evaluation: MASI, serial photograph	100 patients	TA cream is safer than HQ cream as mono-therapy	Mild erythema and irritation
Deo <i>et al.</i> <sup>17</sup> (2013) RCT, single-blind	Group A (kojic acid 1% cream), group B (kojic acid 1% + hydroquinone 2% cream), group C (kojic acid 1% and betamethasone valerate 0.1% cream), group D (kojic acid 1%, hydroquinone 2%, and betamethasone valerate 0.1% cream). Duration: 12 weeks Evaluation: MASI, Wood's light lamp	80 patients	Group B is more effective treat melasma. 60% excellent à MASI score in group B, followed by group A and D (25% excellent reduction) and group C (10%, excellent reduction). Kojic acid and hydroquinone are tyrosinase inhibition that can lighten skin due to antioxidant activity that # depigmenting effect and inhibits melanogenesis.	Solitary patients in group A and two patients in group B had burning sensation while in group D only one person who had acneiform eruptions.
Yenny. <sup>18</sup> (2018) RCT, single-blind	5% methimazole cream (right cheek) than 4% kojic acid (left cheek) Duration: 12 weeks Evaluation: MASI	90 Padang patients	Both methimazole and kojic acid cream have in the same way in inhibiting the activity of tyrosinase (kojic acid inactive chelates the Cu that have a role in tyrosinase process and methimazole inhibit peroxidase) that has the main role in melanogenesis.	5% methimazole has a higher effect in decreasing MASI score and safer than 4% kojic acid. Redness, itching, and burning
Farshi, Mansouri, Kasraee. <sup>19</sup> (2017) RCT, double-blind	cysteamine cream and placebo Duration: 4 months Evaluation: skin colorimetry, dermacatch, MASI scores, patient questionnaires, and Investigator Global Assessments (IGAs).	40 Indian patients with Fitzpatrick skin types III, IV, and V (20 people got cysteamine cream and 20 people got place during that treatment)	Cysteamine cream can be used as an alternative treatment. Concentration is a radioprotector that can à tyrosinase activity and # produce pheomelanin, inhibit DNA polymerase and cell progression that inhibit melanogenesis.	Erythema grade and itching grade I, dryness, burning grade I).
Mansouri <i>et al.</i> <sup>20</sup> (2015) RCT, double-blind	5% Cysteamine cream or placebo Duration: 4 months Evaluation: MASI, Investigator's Global Assessment (IGA )	53 people with Fitzpatrick skin type III, IV and V	Cysteamine can be used as a melasma topical treatment alternative. Cysteamine is inhibitors of peroxidase and tyrosinase, inhibit melanin synthesis that produces depigmentation	Erythema, burning, itching, or and dryness.
<b>Dual combination therapy</b>				
Gold <i>et al.</i> <sup>21</sup> (2013) RCT, open-label	4% Hydroquinone + 0.05% Tretinoin Cream every evening Duration: 24 weeks Evaluation: MASI, Patient quality of life questionnaire	37 patients (only 34 completed it)	Shorter therapy duration compared (effects can be seen significantly since four weeks) to other topical/ Patient quality of life # from 78% felt embarrassed about their skin at week four into only 4% that felt embarrassed at week 24	A few respondents complained of erythema, peeling, burning, dryness, and stinging
Grimes dan Watson. <sup>22</sup> (2013) RCT, single-blind	Combination 4% hydroquinone skin + tretinoin cream 0.025% Duration: 12 weeks Evaluation: MASI	20 Female patients with Fitzpatrick skin types III to VI	Shorter duration therapy than tretinoin or hydroquinone monotherapy.	Fewer respondents complained of peeling, dryness, erythema, and stinging sensation



Ibrahim <i>et al.</i> <sup>23</sup> (2015) RCT, single-blind	Group I (4% hydroquinone), group II (4% hydroquinone + 10% glycolic acid cream), group III (4% hydroquinone + 0.01% hyaluronic acid cream), group IV (4% hydroquinone + 10% glycolic acid + 0.01% hyaluronic acid), and group V (placebo cream). Duration: 6 months Evaluation: mMASI, dermascope	106 Egypt patients (100 completed)	Group III (4% hydroquinone + 0.01% hyaluronic acid cream) was more effective efficacy than group I and had less irritant than others. Group II (4% hydroquinone + 10% glycolic acid cream) was effective for dermal melasma.	Group II showed the highest rate severe of side effects (irritant, mild pruritus, erythema) followed by group IV (70%) of patients (10% of the patient complained of mild pruritus, 30% of patients have mild-to-moderate erythema, 20% have mild scaling, and 10% patients suffered from moderate crustation), the group I (60% of patients), group III (20%) patients were suffering from mild pruritus). No side effect was reported in group V. Recurrence was reported in 6 patients (30%) in group I and four patients (20%) in group III
<b>Triple combination therapy</b>				
Ahmad <i>et al.</i> <sup>24</sup> (2019) RCT, single-blind	Combination cream between: 4% Hydroquinone (HQ), 0.05% tretinoin 0.05%, and 0.01% fluocinoloneacetonide Duration: 8 weeks Evaluation: MASI	22 Iran women	Each composition maximizes the work of other compositions and minimizes side effects. # Skin density because of remodeling effect on collagen and elastin fibers and deposition of glycosaminoglycans. Fluorinated à irritation potential. No significant changes were found in skin hydration, erythema, sebum, and pH. Twice weekly application of combination cream for six months was more effective and had a lower relapse in severe melasma.	Almost all participants experienced scaling, some degrees of pruritus, and erythema around the first month of cream usage
Pekmezci <i>et al.</i> <sup>25</sup> (2019) Retrospective, single-blinded	Combination cream between Azelaic acid (4%), methylprednisolone aceponate (0.04%), hydroquinone (1.6%), and salicylic acid (2%). Duration: 6 months. Evaluation: MASI & PSAS	68 Turkey female patients with Fitzpatrick skin types II-IV.	62% of the total decrease in MI (Melanin Index) in the first three months. The active material combination can abort undesirable effects of another one and creates synergic effects	Irritations were expressed at the beginning of treatment for the first two weeks. Hypertrichosis occur at 6th month of therapy
Fragoso, Tirano, Ponce. <sup>26</sup> (2015) RCT, single-blinded	Triple combination that consist of arbutin 5% + kojic acid 2% + glycolic acid 10% for group A (33 patients) & hydroquinone 4% from group B group (30 patients). Both groups applied creams daily at night. Duration: 3 months Evaluation: MASI & the Spanish-Melasma Quality of life questionnaire [Sp-MelasQoL])	63 Mexicans women	The triple combination is as effective as hydroquinone usage due to the material combination.	Erythema, burning and irritation in both groups, although most occur in group A.
Sardesai, Kolte, dan Srinivas. <sup>27</sup> (2013) RCT	Regimen I (3% Kojic acid +2% Vitamin C cream), regimen II (20% Azelaic acid cream), regimen III (2% Hydroquinone + 0.025% Tretinoin + 0.1% Mometasone furoate cream), regimen IV (5% Arbutin + 0.5% Glabridin cream), regimen V (5% Arbutin + 10% Glycolic acid + 3% Kojic acid cream) Duration: 3 months Evaluation: MASI & Wood light lamp	160 Indian patients that consist of 127 females and 33 were males with age above 18 years	The combination between regimen bring good effect to suppress melasma such as Tyrosinase inhibitors (azelaic acid, hydroquinone, kojic acid, arbutin, glabridin), Inhibitors of melanin production (ascorbic acid, etc.) and non-selective suppressor of melanogenesis (corticosteroids)	Erythema, dryness, burning sensation, and desquamation. Side effects were more occurs on the most effective regimen composition.
Majid <i>et al.</i> <sup>28</sup> (2010) Retrospective study	Mometasone-based triple combination treatment (2% hydroquinone, 0.025% tretinoin, and 1% mometasone) Duration: at least three weeks anytime in a year Evaluation:	60 Indian patients	Can treat mild melasma, has good efficacy if it uses in right duration	Telangiectasia, skin atrophy, acneiform eruption, and hypertrichosis due to usage in the long term more than recommendation because melasma relapse occurs when they try to stop the treatment.

## Oral treatments

### *Tranexamic acid (TA)*

An oral agent is another additional treatment for melasma. Several studies about oral treatments of melasma have been studied for a long time and remain an interesting topic to study. Tranexamic acid (TA) is currently used via oral, topical, intradermal, and micro-needling. Multiple studies have documented the efficacy of TA in patients with melasma. A double-blind RCT study by Del Rosario et al. assessed the efficacy of TA 250 mg twice daily versus placebo in a 3-month study, followed by three months of sunscreen only. Thirty-nine patients completed the trial with outcomes mMASI decreased over time in both groups, with those on the TA group decreasing more than placebo groups at 12 weeks. No serious adverse events were reported, but side effects more occur in the TA group.<sup>29</sup> Another double-blind RCT study by Shin et al. assessed combination oral TA 750 mg daily with laser versus laser only showed greater improvement of MASI scores in the combination treatment group. Forty-four patients were completed for eight weeks of study. Oral TA medication might enhance the efficacy of laser treatment but require long durations of treatment to achieve noticeable skin lightening and were associated with several undesirable side effects.<sup>30</sup>

### *Polypodium leucotomos (PL)*

There has been much interest recently in the use of polypodium leucotomos (PL) as an adjunct photoprotective agent in melasma. Mechanisms of PL include the promotion of the p53 suppressor gene expression, modulation of inflammatory cytokines, upregulation of endogenous antioxidant systems, and blockade of UV radiation-induced cyclooxygenase-2 expression.<sup>31,32</sup> Several recent studies have documented a beneficial effect in patients with melasma. A double-blind RCT study of 40 patients by Goh *et al.* assessed the efficacy of PL 240 mg twice daily versus placebo for 12 weeks. PL group has a significantly greater reduction in MASI score at 56 and 84 days of treatment.<sup>33</sup> In a randomized, placebo-controlled study of 40 patients by Martin *et al.* assessed the efficacy of PL 240 mg twice daily versus placebo. The PL group had significantly improved mean MASI. A photographic assessment revealed mild improvement in 43% of subjects receiving PL compared to 17% of placebo and marked improvement in 14% of subjects receiving PL compared to 0% of placebo. MelasQoL parameters were reported as worsened in 50% of placebo compared to 20% of PL subjects. Overall, this study stated the well-tolerated and effective PL as an adjunctive treatment option, but it is not

efficient to consume orally twice daily for long weeks to treat melasma.<sup>34</sup>

### *Miscellaneous agents*

There were several miscellaneous dietary supplements such as glutathione (GSH) and carotenoid. GSH is one of the most powerful endogenous antioxidants produced by cells in the human body and is a tripeptide of glutamate, cysteine, and glycine. Mechanisms that induce lightening of the skin include inhibition of tyrosinase and the ability to skew production of eumelanin to pheomelanin.<sup>35,36</sup> Previous double-blind RCT study with sixty patients was reported by Weschawalit et al., which evaluate glutathione as antiaging and anti-melanogenic. Patients were divided into three groups include GSH 250 mg daily, oxidized form (GSSG) 250 mg daily and placebo for 12 weeks. Its results tend to decrease UV spots and increased skin elasticity on GSH and GSSG groups compared with placebo. No major adverse events were reported, but increased serum transaminase occur on two patients, highlighting that blood chemistry should be performed.<sup>37</sup>

Nowadays, many natural agents were developed. Carotenoid is a naturally pigmenting extract from plants, algae, and photosynthetic bacteria that have effects on anti-inflammatory, antioxidant, and photoprotection aging.<sup>38</sup> A double-blind RCT study was performed by Teo et al. of 44 patients assessed efficacy 800 mg carotenoid versus placebo in 84 days. In the end, the median mMASI score significantly in both groups, and there was more decrease in the treatment group. Erythema score also showed greater improvement in treatment groups compare to placebo.<sup>39</sup>

## Procedural treatments

### *Chemical peels*

Several procedural treatments had been studied and interest to develop, such as chemical peel, micro-needling, and laser and light therapy. Chemical peels have been used in several studies, but most have not shown superior efficacy to topical agents.<sup>40</sup> Some evidence showed a moderate quality of serial chemical peels with glycolic acid (GA), salicylic acid, or trichloroacetate acid (TCA) were effective in melasma treatment. Superficial and medium depth peels have been used and generate a good result in melasma treatment, but chemical peels can cause irritation and inflammation that can lead to relapse of melasma.<sup>41,42</sup>

Several studies reported glycolic acid as a chemical peeling agent of the skin. A double-blind, RCT study in 40 Indian patients with melasma by Mahajan *et al.*<sup>43</sup> found that low potency triple

**Table 2. Oral melasma treatment studies**

Author, year, study design	Treatment	N	Advantages	Disadvantages
Del Rosario et al. (2017) RCT, double-blind	Group A TA 250 mg BID + sunscreen Group B Placebo BID + sunscreen Duration: 3 months baseline pills, six months evaluation with sunscreen only Evaluation: photography, mMASI, pill count, melanin index, QOL questionnaire	44 patients (39 completed)	Might treat moderate-severe melasma who do not respond with standard therapy No serious adverse effect	Side effect occurred in 63.6% of patients on Group A, gastrointestinal discomfort, change in menstrual period, myalgias, headache, arthralgias, blurry vision
Sin et al. (2013) RCT, double-blind	Combination oral TA 750 mg daily + low-fluence QSNY laser versus low-fluence QSNY laser treatment only Duration: 8 weeks Evaluation: Photography, mMASI,	48 patients (44 completed)	Oral TA medication might enhance the efficacy of laser treatments Reduce refractory melasma by conventional treatment	Require long durations of treatment to achieve noticeable skin lightening and are associated with several undesirable side effects, including skin irritation and paradoxical post-inflammatory hyperpigmentation, especially in Asian patients
Goh et al. (2018) RCT, double-blind	PL 240 mg BID + topical 4% hydroquinone and sunscreen SPF 50 versus Placebo BID + topical 4% hydroquinone and sunscreen SPF 50 Duration: 12 weeks Evaluation: mMASI, skin colorimeter, photography, MelasQoL	40 patients (35 completed)	PL accelerates the pigmentation clearance of melasma compared to those treated with topical 4% hydroquinone and sunscreen alone. No significant side effects were reported throughout the study	PL usage alone is not recommended. It must be accompanied by sunscreen and avoidance of sun exposure during the peak hours of the day
Martin et al. (2012)	PL 240 mg BID + sunscreen SPF 45 versus Placebo + sunscreen SPF 45 Duration: 12 weeks Evaluation: MASI, Photography, MelasQoL	21 patients	PL is well tolerated and effective in patients with Melasma and importance as an adjunctive treatment option	Most patients were not interested in purchasing and ingesting an oral medication three times daily Less efficient to consume oral drugs three times a day for long weeks to treat melasma
Weschawalit et al. (2018) RCT, double-blind	Group A: GSH 250 mg daily Group B: GSSG 250 mg daily Group C: Placebo Duration: 12 weeks Evaluation: Melanin index (Maxameter), photography, TEWL, Corneometer, Cutometer, Visioscan	60 patients (57 completed)	Glutathione in both forms is well tolerated. No major adverse events took place during the study period.	Adverse reactions included pruritus, macular erythema, transient minute red spots on the skin, and tiredness Increases in transaminases occurred in two subjects highlighting the fact that blood chemistry should be performed even when individuals are taking over-the-counter supplements
Teo et al. (2015) RCT, double-blind	An oral supplement containing carotenoid + lightening cream versus placebo + lightening cream Duration: 84 days Evaluation: mMASI, photography, melanin and erythema index using Maxameter	44 patients (36 completed)	Active supplement carotenoid potentially has an adjunctive treatment No major side effects have reported	Need further larger scale and longer studies



combination (HQ 2%, tretinoin 0.05%, fluocinonide 0.01%) and glycolic acid peels/ azelaic acid 20% cream resulted in a low significant reduction in MASI and VAS. Both low potency TC cream and GA/AA 20% cream combination are effective in treating melasma among Indian patients. All patients used broad-spectrum sunscreen with SPF 30 to minimize the side effects. Another study by Sarkar *et al.*<sup>44</sup> compared glycolic acid 35% peel, salicylic-mandelic acid, and phytic combination peels in 90 Indian patients with melasma for 20 weeks. The decrease MASI score in glycolic acid 35% peel, and salicylic-mandelic acid was significantly lower than phytic combination peels, but no significant difference between the glycolic acid peel and salicylic-mandelic acid peel. Salicylic-mandelic acid peel is a combination of alpha and beta hydroxy acid. Mandelic acid is an ideal peeling agent for sensitive skin because it is associated with a less stinging and burning sensation. Glycolic acid has a good response in Asian and Black patients with melasma.<sup>44</sup> Garg *et al.* compared the use of three different chemical peels: 35% GA full-face peel, 35% GA full-face peel followed by a 10% TCA spot peel, and 35% GA full-face peel followed by a 20% TCA spot peel once every 15 days in 30 patients. All the groups had a significant decrease in MASI. Hence, a combination of GA and TCA peels does not increase the efficacy of melasma treatment while they may increase the side effects.<sup>45</sup>

Salicylic acid peels are well tolerated in all skin types.<sup>44</sup> A randomized control trial by Balevi *et al.* compared 30% salicylic acid peel and 30% salicylic acid peel + vitamin C intradermally in 50 patients. MelasQoL and MASI scores decreased significantly in both groups. Salicylic acid peels combined with vitamin C intradermally produced better results in terms of the MASI and MelasQoL scores. The effect of salicylic acid peels increased when combined with intradermal vitamin C since it had no damage to the epidermis.<sup>46</sup>

TCA is a versatile chemical peeling that has the ability to create superficial, medium, and deep peels based on strength. A recent randomized study by Murtaza *et al.* compared a combination of 20% TCA peel + magnesium ascorbyl phosphate (MAP) cream once daily with TCA peels alone in 148 patients for six weeks. The combination group has shown a significant decrease in MASI scores than the chemical peel group only. The efficacy of TCA peel + MAP cream is more effective compared to TCA peel alone.<sup>47</sup> Another non-randomized control study by Puri compared 15% TCA peel and 35% glycolic acid peel in 30 patients. Both of the groups are significantly reduced MASI scores and equally effective in treating melasma.<sup>48</sup> TCA

is stable, inexpensive, and causes no systemic toxicity. TCA has more side effects compared to glycolic acid peel, such as erythema, burning sensation, desquamation, hyperpigmentation, and cracking.<sup>47,48</sup>

#### *Laser and light-based therapy*

Laser and light-based therapy are additional therapy for melasma. They had an unpredictable response and also caused recurrent pigmentation symptoms. Intense Pulsed Light (IPL) therapy uses a flash lamp that emits noncoherent light with wavelengths between 515-1200 nm. The filter targets selective chromophores (melanin, hemoglobin) and is used to treat pigmentation disorders, including melasma. IPL therapy results in modest improvement on melasma patients with refractory to topical therapy alone.<sup>5</sup> Laser therapy also became an alternative to treat melasma, especially in refractory and resistance cases. Due to the high recurrence rate, laser therapy is only recommended for persistent melasma cases that have failed the other laser and light-based therapy modalities.<sup>5,49</sup>

A randomized trial by Goldman *et al.* compared IPL with a triple combination cream (TCC) and IPL with a placebo cream (PC) in moderate to severe melasma for ten weeks in 56 patients. Improvement in melasma was significantly greater in TCC and IPL than with placebo cream and IPL. This showed that IPL could be helpful to treat melasma if combined with an aggressive topical maintenance treatment to minimize pathways for the recurrence pigmentation.<sup>50</sup> Another similar study by Figueiredo & Trancoso compared IPL with TC cream versus TC cream alone in 62 patients for 48 weeks. Single-session IPL followed by TCC was more effective than TCC therapy alone.<sup>51</sup> In a randomized control trial, Shakeeb *et al.* also compared TCC alone, IPL alone, and IPL with TCC in 96 patients for eight weeks. MASI score reduction was 68.8% in group A, 62.5% in group B and 93.8% in group C. Decrease in MASI was higher in Group C compared to Groups A and B. Combination of IPL therapy and TCC is significantly more efficacious than IPL therapy and TCC alone.<sup>52</sup>

Low fluence Q-switched (LFQS) Nd: YAG laser was the most commonly evaluated laser in melasma. Several studies identified the combination of laser and laser alone shown some improvement in treating melasma.<sup>5</sup> Hence, laser monotherapy is not recommended in melasma due to recurrent pigmentation. The maintenance schedules must be continued altogether with topical treatment for melasma.<sup>53</sup> A prospective study by Hofbauer Parra *et al.* treated 20 patients with a low-fluence 1064-nm QS Nd: YAG laser for ten weeks. It was found

**Table 3. Procedural Melasma Treatment Studies**

Author, year, study design	Treatment	N	Advantages	Disadvantages
<b>Chemical peels</b>				
Mahajan, et al. (2015) RCT, double blind	TC (HQ 2%, tretinoin 0.05%, fluocinolone 0.01%) versus GA peels/ AA 20% cream Duration: 12 weeks Evaluation: digital photography, MASI, VAS	40 Indian patients (38 completed)	GA peels improved surface texture, appearance, and photodamaged. The exfoliative effect of GA peels stimulates new epidermal growth and collagen.	Four patients from TC and three patients from GA/AA 20% cream experienced irritation, dryness, and photosensitivity
Sarkar <i>et al.</i> (2016) RCT, single-blind	Group A GA-35% peel Group B 20% Salicylic and 10% Mandelic acid Group C phytic combination peels Duration: 20 weeks Evaluation: MASI, photography	90 Indian patients	GA and SM acid peels are both equally efficacious and safe for treating melasma in Indian skin. SM peels are a more suitable tolerance for Indian skin. GA gives a good response in epidermal and melasma in Asian and Black patients.	Group A: 19% mild erythema and desquamation, 15% PIH Group B: 25% burning sensation Group C: 32% burning sensation
Garg <i>et al.</i> (2019) RCT, double-blind	Group A: 35% GA full-face peel Group B: 35% GA full-face peel + 10% TCA spot peel Group C: 35% GA full-face peel + 20% TCA spot peel Duration: once every 15 days for eight weeks Evaluation: MASI	30 patients	GA peels or in combination with TCA are resulting in a significant improvement in melasma.	Persistent local erythema, pruritus burning sensation, and transient hyperpigmentation. A combination of GA and TCA peels does not improve the efficacy, while they may increase the side effects.
Balevi <i>et al.</i> (2017) RCT, single blind	Group A: 30% SA peel Group B: 30% SA peel + vitamin C intradermally Both protected with SPF 15 or higher 2-3 times daily. Duration: every two weeks for two months Evaluation: MASI, MelasQoL	50 patients	SA peel + vitamin C mesotherapy is safe and effective for the treatment of melasma with no significant side effects and minimal downtime.	Mild to a moderate burning sensation.
Murtaza <i>et al.</i> (2016) RCT	Group A: 20% TCA peel + MAP 5% topical Group B: 20% TCA peel Duration: 6 weeks Evaluation: MASI	148 patients	The Efficacy of combination TCA and MAP is more effective compared to TCA peel alone.	Erythema, burning sensation, desquamation
Puri. (2012) Non-randomized Comparative	Group A: 15% TCA peel Group B: 35% GA peel Duration: every three weeks (maximum six times) Evaluation: MASI	30 patients	TCA has a versatile ability to create superficial, medium, and deep peels. It is stable, inexpensive, and causes no systemic toxicity.	Burning/ stinging, scarring, folliculitis, pain, hyperpigmentation, Post-peel cracking TCA had more side effects.
<b>Laser and light-based therapy</b>				
Goldman <i>et al.</i> (2011) Randomized, single-blind	One side: IPL + TCC Contralateral side: IPL + placebo cream Duration: 2 sessions, at week 4 and 6 for ten weeks Evaluation: IGA	56 patients	A combination of TCC and IPL is an effective and safe treatment option for patients with melasma.	The combination of TC cream and IPL had more adverse effects than placebo cream and IPL. The adverse effects such as erythema, scaling, dryness, telangiectasia, and burning sensation.

Figueiredo & Trancoso. (2012) Randomized, open-label	Group A: IPL + TCC Group B: TCC alone Duration: 48 weeks Evaluation: MASI, IGA	62 patients	Single-session IPL combined with TCC treatment is safe and effective refractory mixed and dermal melasma.	Temporary side effects were associated with IPL treatment, such as mild erythema and pain.
Shakeeb <i>et al.</i> (2018) RCT	Group A: TCC alone Group B: IPL alone Group C: IPL + TCC Duration: 8 weeks TCC daily at night IPL 4 session every two weeks Evaluation: MASI	96 patients	The combination of IPL therapy and TCC is significantly more effective than IPL therapy and TCC alone.	Side effects are not mentioned.
Hofbauer Parra <i>et al.</i> (2016) Prospective	low-fluence 1064-nm QS Nd: YAG laser Duration: 10 weeks (interval one weeks) Evaluation: MASI	20 patients	low-fluence QS Nd: YAG laser is safe and effective for treating melasma. Long term effect was poor due to the high recurrence rate in monotherapy.	Temporary mild erythema and local warmth
Lee <i>et al.</i> (2013) RCT, double-blind	Group A: 1064-nm QSNYL + placebo chemical peeling Group B: 1064-nm QSNYL + Jessner's solution chemical peeling Duration: 20 weeks (2 weeks interval) Evaluation: MASI, PGA, the self-assessment	52 patients	Combination of Jessner's peel with low-fluence 1064-nm Q-switched Nd: YAG laser is a safe and effective method in the early course of melasma treatment.	Burning sensation during and after Jessner's solution Application.
Vachiramonet <i>al.</i> (2015) RCT, single blind	Low-fluence QSNd: YAG 1064 nm to the entire face vs. additional 30% GA peel to one side Duration: 16 weeks (5 weekly sessions) Evaluation: MASI, RL*I, patient self-assessment SPF 50 once daily	12 patients	No significant difference in relative lightness the index between both sides.	Burning or stinging, guttate hypopigmentation
Vachiramonet <i>al.</i> (2015) RCT, single blind	Low-fluence QSNd: YAG 1064 nm to the entire face (5 weekly sessions) vs. additional IPL on one side (3 sessions) Duration: 12 weeks Evaluation: MASI, RL*I, patient satisfaction	20 patients 18 completed	Both sides of the face showed significant improvement of R*LI and MASI. A more rapid improvement was observed on the combined side. Recurrence occurred on both sides.	Slight erythema and mild stinging on both sides and was resolved within one day.
<b>Microneedling</b>				
Saleh <i>et al.</i> (2019) The prospective, randomized study, double-blind	Group I: micro-needling (6 sessions) + topical TXA Group II: micro-needling alone (6 sessions) Duration: 12 weeks (2-week interval) Evaluation: MASI	42 patients	Microneedling is safe and effective to decrease epidermal hyperpigmentation and dermal melanophages	Slight transient erythema and burning sensation
Budamakuntla <i>et al.</i> (2013) A prospective, randomized, open-label study	Group A: localized microinjection of TXA Group B: TXA + micro-needling Duration: 11 weeks (4-weeks interval) Evaluation: MASI, PGA, PtGA	60 patients	Micro-needling results in a good response of MASI scores due to the deeper and uniform delivery of medication.	Itching, burning sensation, and erythema in both groups.

that low-fluence QS Nd: YAG laser is effective in reducing MASI scores, but the recurrence rate was high.<sup>54</sup> Another study by Lee *et al.* compared 1064-nm QSNYL + placebo chemical peeling with 1064-nm QSNYL + Jessner's solution chemical peeling for 20 weeks in 52 patients. Significant decrease in MASI scores at eight weeks in all groups. There was no significant difference in MASI score, PGA, and self-assessment at 20 weeks.<sup>55</sup> Vachirammon *et al.* also compared low-fluence QSNd: YAG 1064 nm to the entire face versus an additional 30% GA peel to one side for 16 weeks in 12 patients. There was no significant difference between both treatments in RL\*I and mMASI score. But patient self-assessment was more favorable in the combined treatment.<sup>56</sup> In another study, Vachirammon also compared low-fluence QSNd: YAG 1064 nm to the entire face versus additional IPL on one side for 12 weeks in 20 patients (18 completed), shown significant improvement in both sides of the face. Recurrence occurred on both sides.<sup>57</sup>

#### Microneedling

Microneedling uses a fine needle instrument, which is rolled over the skin to create some punctures. The treatment results in a wound-healing response and produces collagen and elastin. This technique is also used to enhance transdermal drug delivery through the stratum corneum. Microneedling decreases the risk of many adverse effects that can occur with conventional resurfacing modalities. Microneedling keeps the epidermis partially intact, and it hastens the recovery also minimize the risk of infection and scarring.<sup>58</sup>

A prospective randomized study by Saleh *et al.* compared the efficacy of topical tranexamic acid with micro-needling versus micro-needling alone in melasma treatment. It has shown a significant decrease in MASI scores in both groups. There was a significantly higher reduction of MASI scores in topical tranexamic acid with micro-needling compared to micro-needling alone. Epidermal hyperpigmentation and dermal melanophages were significantly reduced after treatment. Microneedling alone produced a significant lightening effect, but topical TXA combined with micro-needling achieved more satisfactory results.<sup>59</sup> Another study by Budamakuntla *et al.* compared the therapeutic efficacy and safety of tranexamic acid microinjections versus tranexamic acid with micro-needling in melasma patients. The results showed a 35.72% improvement of MASI scores in the microinjection group compared to 44.41% in the micro-needling group. Tranexamic acid microinjection can be used as a potential and effective in melasma treatment. Microneedling

group resulted in a better response to treat melasma because it attributed to the deeper and uniform delivery of medication through the microchannels.<sup>60</sup>

## DISCUSSION

Melasma remains therapeutically challenging, despite various treatment options available with multimodality. Treatment efficacy can vary due to several factors, including variability in clinical presentation and response to treatment amongst different genders, skin phototypes, and ethnicities. The effect of treatment also depends on the treatment time, the usage concentration, and the addition of other components. A detailed history should be taken for each patient to exclude individuals at risk for untoward complications.

Hydroquinone has remained the most effective agent both in topical treatment and chemical peeling, but concerns regarding its side effect remain. The HQ combination usages with other topical agents were suggested to reduce its side effects and increase the efficacy.<sup>21,22</sup> The most recommend formula in triple combination cream is Kligman and Willis formula (5% HQ, 0.1% dexamethasone, and 0.1% tretinoin) because it can decrease MASI score significantly, increase and maximize the efficacy and performance of every topical agent in that combination, shorter duration of treatment, and minimize the side effects of regimen usage.<sup>21,22,27</sup> In addition to this well-established classic combination, other agents such as niacinamide<sup>11</sup>, azelaic acid<sup>12,13</sup>, glycolic acid<sup>6,23-26</sup>, corticosteroid<sup>6</sup>, tretinoin<sup>21</sup>, kojic acid<sup>17-18</sup>, and vitamin C<sup>6,27</sup> have shown good results, either as an active or supporting cast of other bleaching substances. However, neither of them clinically obtained the same power of hydroquinone effect, but they had fewer adverse effects.<sup>6</sup>

Oral and topical tranexamic acid has been found to be a useful adjuvant treatment in refractory melasma with minimal adverse effects. However, rare adverse effects reported include myocardial infarction, visual disturbance, anaphylaxis and pulmonary embolism. It emphasizes that screening personal and familial risk factors of thromboembolism should be needed before initiation.<sup>29,30</sup> Another oral agent is Polypodium leucotomos that reported to have antioxidant, anti-inflammatory, and photoprotective properties. PL is not recommended as monotherapy. It must be accompanied by sunscreen and avoidance of sun exposure during the peak hours of the day.<sup>31-33</sup> Overall, the advantages of oral therapy are convenient, easy to administer, and generally preferred by patients. In addition, its antioxidant effect can protect against photodamage deeper down

to the cellular level. However, the disadvantages of oral therapy are it may be unsuitable for those who do not want or cannot take oral medications for long days. The efficacy of oral agents can also influence by stomach acid and enzyme degradation.

From procedural treatment studies reviewed, skin micro-needling was reported resulting in sustained long-term improvement because it stimulates fibroblast proliferation, the release of growth factors and collagen production.<sup>58</sup> Microneedling keeps the epidermis partially intact and minimizes the risk of infection and scarring. However, not many studies have discussed the efficacy of micro-needling. Several studies have recommended a combination of topical agents to reduce side effects.<sup>59,61</sup> Laser and light-based therapy have a limited role in melasma treatment. Laser and light-based therapy had an unpredictable response and also caused recurrent pigmentation symptoms. Laser therapy became an alternative to the treatment of melasma, especially for patients with refractory and resistance cases.<sup>5</sup>

Regarding the methodology of the study, most of the studies in this review used outcome measures based on clinical examination and photographic evaluation. Serial photography is essential in the clinical management of hyperpigmentation, especially helpful when patients think treatment is not working. MASI score and mMASI score were the most common scoring for evaluation. In the case of melasma, a gradual reduction in the intensity of pigmentation over all the areas of the face simultaneously shows a positive response to treatment, even a small reduction in pigment intensity. However, because of the overdependence on the “area” variable, MASI or mMASI score is not adequate to reflect this positive response to treatment sensitively. Some studies also using non-validated measure outcomes such as patient self-assessment. The patient self-assessment has become as valuable as a professional’s assessment to judge the progression of treatment over time. Physicians who treat patients with melasma should be aware of its profound psychosocial effects and the improvement that successful melasma treatment can have on self-esteem.

It is difficult to compare all the studies because many articles include a non-general term to evaluate the severity. No treatment for melasma has demonstrated truly satisfactory results, and so far, it is unclearly stated that these treatments have been demonstrated to prevent frequent relapses. With so many options, it can be hard to decide which treatment is the most optimal because the approach treatment of melasma depends on the region, type, and severity of melasma. Better studies using objective and validate outcome measures, a large

sample size, and longer follow-up are needed.

## CONCLUSION

In conclusion, the current state of the evidence suggests that some treatments with multiple modalities have their respective advantages and disadvantages. The choice of treatment modality must be adjusted according to the type of melasma, such as its severity, extent and location. A better understanding of melasma through further research may improve the therapy options with the least adverse effects.

## CONFLICT OF INTEREST

None declared.

## FUNDING

Authors own funding.

## AUTHORS CONTRIBUTION

All authors contributed to this publication.

## REFERENCES

1. Handel A, Miot L, Miot H. Melasma: a clinical and epidemiological review. *Anais Brasileiros de Dermatologia*. 2014;89(5):771-782. DOI: [10.1590/abd1806-4841.20143063](https://doi.org/10.1590/abd1806-4841.20143063)
2. Jiang J, Akinseye O, Tovar-Garza A, Pandya AG. The effect of melasma on self-esteem: a pilot study. *Int J Womens Dermatol*. 2017;4(1):38–42. DOI: [10.1016/j.ijwd.2017.11.003](https://doi.org/10.1016/j.ijwd.2017.11.003)
3. Guinot C, Cheffai S, Latreille J, Dhaoui MA, Youssef S, Jaber K, et al. Aggravating factors for melasma: a prospective study in 197 Tunisian patients. *J Eur Acad Dermatol Venereol*. 2010;24(9):1060–9 (PubMed PMID: 20202051)
4. Tamega AA, Miot LD, Bonfietti C, Gige TC, Marques ME, Miot HA. Clinical patterns and epidemiological characteristics of facial melasma in Brazilian women. *J Eur Acad Dermatol Venereol*. 2013;27(2):151–6 (PubMed PMID: 22212073)
5. Trivedi MK, Yang FC, Cho BK. A review of laser and light therapy in melasma. *International Journal of Women's Dermatology*. 2017;3(1):11-20. DOI:[10.1016/j.ijwd.2017.01.004](https://doi.org/10.1016/j.ijwd.2017.01.004)
6. McKesey J, Tovar-Garza A, Pandya A. Melasma Treatment: An Evidence-Based Review. *American Journal of Clinical Dermatology*. 2019;21(2):173-225. DOI:[10.1007/s40257-019-00488-w](https://doi.org/10.1007/s40257-019-00488-w)
7. Adalatkah H, Sadeghi-Bazargani H. The first clinical experience on efficacy of topical flutamide on melasma compared with topical hydroquinone: a randomized clinical trial. *Drug Design Development Therapy*. 2015; 9: 4219–4225. DOI: [10.2147/DDDT.S80713](https://doi.org/10.2147/DDDT.S80713). eCollection 2015
8. Shankar K, Godse K, Aurangabadkar S, Lahiri K, Mysore V, Ganjoo A, et al. Evidence-Based Treatment for Melasma: Expert Opinion and a Review. *Dermatology and Therapy*. 2014;4(2):165-186. DOI: [10.1007/s13555-014-0064-z](https://doi.org/10.1007/s13555-014-0064-z)



9. Monteiro R, Kishore B, Bhat R, Sukumar D, Martis J, Ganesh H. A comparative study of the efficacy of 4% hydroquinone vs. 0.75% Kojic acid cream in the treatment of facial melasma. *Indian Journal of Dermatology*. 2013;58(2):157. DOI: [10.4103/0019-5154.108070](https://doi.org/10.4103/0019-5154.108070)
10. Yenny S, Lestari W. Perbandingan Penggunaan Arbutin dan Azelaic Acid untuk Pengobatan Melasma. *Media Dermato Venerologica Indonesiana (MDVI)*. 2013;40(4):154-158.
11. Navarrete-Solís J, Castanedo-Cázares J, Torres-Álvarez B, Oros-Ovalle C, Fuentes-Ahumada C, González F et al. A Double-Blind, Randomized Clinical Trial of Niacinamide 4% versus Hydroquinone 4% in the Treatment of Melasma. *Dermatology Research and Practice*. 2011;2011:1-5. DOI: [10.1155/2011/379173](https://doi.org/10.1155/2011/379173)
12. Farshi S. Comparative study of therapeutic effects of 20% azelaic acid and hydroquinone 4% cream in the treatment of melasma. *Journal of Cosmetic Dermatology*. 2011;10(4):282-287. DOI: [10.1111/j.1473-2165.2011.00580.x](https://doi.org/10.1111/j.1473-2165.2011.00580.x)
13. Bansal C, Chauhan A, Kar H, Naik H. A comparison of low-fluence 1064-nm Q-switched Nd: YAG laser with topical 20% azelaic acid cream and their combination in melasma in Indian patients. *Journal of Cutaneous and Aesthetic Surgery*. 2012;5(4):266. DOI: [10.4103/0974-2077.104915](https://doi.org/10.4103/0974-2077.104915)
14. Ebrahimi B, Fatemi Naeini F. Topical tranexamic acid as a promising treatment for melasma. *J Res Med Sci* 2014;19:753-7 (PubMed PMID: 25422661)
15. Hassan A, Hassan G, Ismail M, El-Maghraby G. A comparative study between two topical treatments (tranexamic acid and flutamide) in the treatment of patients with melasma. *Journal of the Egyptian Women's Dermatologic Society*. 2018;15(3):144-150. DOI: [10.1097/01.EWX.0000546169.90015.65](https://doi.org/10.1097/01.EWX.0000546169.90015.65)
16. Janney M, Subramaniyan R, Dabas R, Lal S, Das N, Godara S. A Randomized Controlled Study Comparing the Efficacy of Topical 5% Tranexamic Acid Solution versus 3% Hydroquinone Cream in Melasma. *Journal of Cutaneous and Aesthetic Surgery*. 2019;12(1):63-67. DOI: [10.4103/JCAS.JCAS\\_40\\_18](https://doi.org/10.4103/JCAS.JCAS_40_18)
17. Deo K, Dash K, Sharma Y, Virmani N, Oberai C. Kojic acid vis-a-vis its combinations with hydroquinone and betamethasone valerate in melasma: A randomized, single-blind, comparative study of efficacy and safety. *Indian Journal of Dermatology*. 2013;58(4):281. DOI: [10.4103/0019-5154.113940](https://doi.org/10.4103/0019-5154.113940)
18. Yenny S. Comparison of the Use of 5% Methimazole Cream with 4% Kojic Acid in Melasma Treatment. *Turkish Journal of Dermatology*. 2018;12(4):167-171. DOI: [10.4274/tdd.3640](https://doi.org/10.4274/tdd.3640)
19. Farshi S, Mansouri P, Kasraee B. Efficacy of cysteamine cream in the treatment of epidermal melasma, evaluating by Dermacatch as a new measurement method: a randomized, double-blind placebo-controlled study. *Journal of Dermatological Treatment*. 2017;29(2):182-189. DOI: [10.1080/09546634.2017.1351608](https://doi.org/10.1080/09546634.2017.1351608)
20. Mansouri P, Farshi S, Hashemi Z, Kasraee B. Evaluation of the efficacy of cysteamine 5% cream in the treatment of epidermal melasma: A randomized, double-blind placebo-controlled trial. *Br J Dermatol*. 2015;173(1):209-217. DOI: [10.1111/bjd.13424](https://doi.org/10.1111/bjd.13424)
21. Gold M, Rendon M, Dibernardo B, Bruce S, Lucas-Anthony C, Watson J, et al. Open-label treatment of moderate or marked melasma with a 4% hydroquinone skincare system plus 0.05% tretinoin cream. *J Clin Aesthet Dermatol*. 2013;6:32-8 (PubMed PMID: 24307923)
22. Grimes P, Watson J. Treating epidermal melasma with a 4% hydroquinone skincare system plus tretinoin cream 0.025%. *Cutis*. 2013;91:47-54. (PubMed PMID: 23461059)
23. Ibrahim Z, Gheida S, El Maghraby G, Farag Z. Evaluation of the efficacy and safety of combinations of hydroquinone, glycolic acid, and hyaluronic acid in the treatment of melasma. *Journal of Cosmetic Dermatology*. 2015;14(2):113-123. DOI: [10.1111/jocd.12143](https://doi.org/10.1111/jocd.12143)
24. Nasrollahi SA, Nematzadeh MS, Samadi A, Ayatollahi A, Yadangi S, Abels C, Firooz A. Evaluation of the safety and efficacy of a triple combination cream (hydroquinone, tretinoin, and fluocinolone) for treatment of melasma in Middle Eastern skin. *Clinical, Cosmetic and Investigational Dermatology*. 2019;12:437-444. DOI: [10.2147/CCID.S202285](https://doi.org/10.2147/CCID.S202285)
25. Pekmezci E. A novel triple combination in treatment of melasma: Significant outcome with far less actives. *Journal of Cosmetic Dermatology*. 2019;18(6):1700-1704. DOI: [10.1111/jocd.12904](https://doi.org/10.1111/jocd.12904)
26. Frago-Covarrubias CE, Tirado-Sánchez A, Ponce-Oliviera RM. Efficacy and safety of the combination of arbutin 5% + glycolic acid 10% + kojic acid 2% versus hydroquinone 4% cream in the management of facial melasma in Mexican women with Fitzpatrick skin type III-IV. *Dermatol Rev Mex*. 2015;59(4):263-270.
27. Sardesai V, Kolte J, Srinivas B. A clinical study of melasma and a comparison of the therapeutic effect of certain currently available topical modalities for its treatment. *Indian Journal of Dermatology*. 2013;58(3):239. DOI: [10.4103/0019-5154.110842](https://doi.org/10.4103/0019-5154.110842)
28. Majid I. Mometasone-based triple combination therapy in melasma: Is it really safe?. *Indian Journal of Dermatology*. 2010;55(4):359. DOI: [10.4103/0019-5154.74545](https://doi.org/10.4103/0019-5154.74545)
29. Del Rosario E, Florez-Pollack S, Zapata Jr, et al. Randomized, placebo-controlled, double-blind study of oral tranexamic acid in the treatment of moderate-to-severe melasma. *J Am Acad Dermatol*. 2018;78(2):363-369. DOI: [10.1016/j.jaad.2017.09.053](https://doi.org/10.1016/j.jaad.2017.09.053)
30. Shin JU, Park J, Oh SH, Lee JH. Oral tranexamic acid enhances the efficacy of low-fluence 1064-nm quality-switched neodymium-doped yttrium aluminum garnet laser treatment for melasma in Koreans: a randomized, prospective trial. *Dermatol Surg*. 2013;39(3 Pt 1):435-442. DOI: [10.1111/dsu.12060](https://doi.org/10.1111/dsu.12060)
31. Nestor M, Bucay V, Callender V, Cohen JL, Sadick N, Waldorf H. Polypodium leucotomos as an Adjunct Treatment of Pigmentary Disorders. *J Clin Aesthet Dermatol*. 2014;7(3):13-17. (PubMed PMID: 24688621)
32. Choudhry SZ, Bhatia N, Ceilley R, et al. Role of oral Polypodium leucotomos extract in dermatologic diseases: a review of the literature. *J Drugs Dermatol*. 2014;13(2):148-153. (PubMed PMID: 24509964)
33. Goh CL, Chuah SY, Tien S, Thng G, Vitale MA, Delgado-Rubin A. Double-blind, placebo-controlled trial to evaluate the effectiveness of Polypodium leucotomos extract in the treatment of melasma in Asian skin: A pilot study. *J Clin Aesthet Dermatol*. 2018;11(3):14-19. (PubMed PMID: 29606995)
34. Ahmed AM, Lopez I, Perese F, et al. A randomized, double-blinded, placebo-controlled trial of oral Polypodium leucotomos extract as an adjunct to sunscreen in the treatment of melasma. *JAMA Dermatol*. 2013;149(8):981-983. DOI: [10.1001/jamadermatol.2013.4294](https://doi.org/10.1001/jamadermatol.2013.4294)
35. Pillaiyar T, Manickam M, Namasivayam V. Skin whitening agents: medicinal chemistry perspective of tyrosinase inhibitors. *J Enzyme Inhib Med Chem*. 2017;32(1):403-425. DOI: [10.1080/14756366.2016.1256882](https://doi.org/10.1080/14756366.2016.1256882)
36. Grimes PE, Ijaz S, Nashawati R, Kwak D. New oral and topical approaches for the treatment of melasma. *Int J Womens Dermatol*. 2018;5(1):30-36. Published 2018 Nov

20. DOI: [10.1016/j.jjwd.2018.09.004](https://doi.org/10.1016/j.jjwd.2018.09.004)
37. Weschawalit S, Thongthip S, Phutrakool P, Asawanonda P. Glutathione and its antiaging and antimelanogenic effects. *Clin Cosmet Investig Dermatol*. 2017;10:147-153. Published 2017 Apr 27. DOI: [10.2147/CCID.S128339](https://doi.org/10.2147/CCID.S128339)
  38. Galasso C, Corinaldesi C, Sansone C. Carotenoids from Marine Organisms: Biological Functions and Industrial Applications. *Antioxidants (Basel)*. 2017;6(4):96. Published 2017 Nov 23. DOI: [10.3390/antiox6040096](https://doi.org/10.3390/antiox6040096)
  39. Teo WL, Gan E, Jinghan A, et al. Double-blind placebo-controlled trial to evaluate the effectiveness of a dietary supplement rich in carotenoids as adjunct to topical lightening cream for the treatment of melasma: a pilot study. *J Pigment Disord* 2015; 2: 164. DOI: [10.4172/2376-0427.1000164](https://doi.org/10.4172/2376-0427.1000164)
  40. Sarkar R, Bansal S, Garg VK. Chemical peels for melasma in dark-skinned patients. *J Cutan Aesthet Surg*. 2012;5(4):247-253. DOI:[10.4103/0974-2077.104912](https://doi.org/10.4103/0974-2077.104912)
  41. Lee BW, Schwartz RA, Janniger CK. Melasma. *G Ital Dermatol Venereol*. 2017;152:36-45. DOI: [10.23736/S0392-0488.16.05425-0](https://doi.org/10.23736/S0392-0488.16.05425-0)
  42. Sheth VM, Pandya AG. Melasma: a comprehensive update: part II. *J Am Acad Dermatol*. 2011;65(4):699-714. DOI: [10.1016/j.jaad.2011.06.001](https://doi.org/10.1016/j.jaad.2011.06.001)
  43. Mahajan R, Kanwar AJ, Parsad D, Kumaran MS, Sharma R. Glycolic Acid peels/azelaic Acid 20% cream combination and low potency triple combination lead to similar reduction in melasma severity in ethnic skin: results of a randomized controlled study. *Indian J Dermatol*. 2015;60(2):147-152. DOI:[10.4103/0019-5154.152510](https://doi.org/10.4103/0019-5154.152510)
  44. Sarkar R, Garg V, Bansal S, Sethi S, Gupta C. Comparative Evaluation of Efficacy and Tolerability of Glycolic Acid, Salicylic Mandelic Acid, and Phytic Acid Combination Peels in Melasma. *Dermatol Surg*. 2016;42(3):384-391. DOI:[10.1097/DSS.0000000000000642](https://doi.org/10.1097/DSS.0000000000000642)
  45. Garg S, Thami GP, Bhalla M, Kaur J, Kumar A. Comparative Efficacy of a 35% Glycolic Acid Peel Alone or in Combination With a 10% and 20% Trichloroacetic Acid Spot Peel for Melasma: A Randomized Control Trial. *Dermatologic Surgery*. 2019;45(11):1394-1400. DOI: [10.1097/DSS.0000000000001964](https://doi.org/10.1097/DSS.0000000000001964)
  46. Balevi A, Ustuner P, Özdemir M. Salicylic acid peeling combined with vitamin C mesotherapy versus salicylic acid peeling alone in the treatment of mixed-type melasma: A comparative study. *J Cosmet Laser Ther*. 2017;19(5):294-299. DOI:[10.1080/14764172.2017.1314501](https://doi.org/10.1080/14764172.2017.1314501)
  47. Murtaza F, Bangash AR, Khushdil A, Noor SM. Efficacy of Trichloro-Acetic Acid Peel Alone Versus Combined Topical Magnesium Ascorbyl Phosphate for Epidermal Melasma. *J Coll Physicians Surg Pak*. 2016;26(7):557-561 (PubMed PMID: 27504543)
  48. Puri N. Comparative study of 15% TCA peel versus 35% glycolic acid peel for the treatment of melasma. *Indian Dermatol Online J*. 2012;3(2):109-113. DOI: [10.4103/2229-5178.96702](https://doi.org/10.4103/2229-5178.96702)
  49. Na SY, Cho S, Lee JH. Intense Pulsed Light and Low-Fluence Q-Switched Nd: YAG Laser Treatment in Melasma Patients. *Annals of dermatology*. 2012;24(3):267-73. DOI:[10.5021/ad.2012.24.3.267](https://doi.org/10.5021/ad.2012.24.3.267).
  50. Goldman MP, Gold MH, Palm MD, Colon LE, Preston N, Johnson LA, Gottschalk RW. Sequential treatment with triple combination cream and intense pulsed light is more efficacious than sequential treatment with an inactive (control) cream and intense pulsed light in patients with moderate to severe melasma. *Dermatologic surgery*. 2011;37(2):224-233. DOI:[10.1111/j.1524-4725.2010.01849.x](https://doi.org/10.1111/j.1524-4725.2010.01849.x)
  51. Souza LF, Souza ST. Single-session intense pulsed light with stable fixed-dose triple combination topical therapy for the treatment of refractory melasma. *Dermatol Ther*. 2012;25(5):477-480. DOI:[10.1111/j.1529-8019.2012.01530.x](https://doi.org/10.1111/j.1529-8019.2012.01530.x)
  52. Shakeeb N, Noor SM, Ullah G, Paracha MM. Efficacy of Intense Pulse Light Therapy And Tripple Combination Cream Versus Intense Pulse Light Therapy And Tripple Combination Cream Alone In Epidermal Melasma Treatment. *Journal of College of Physicians and Surgeons Pakistan*. 2018;28(1):13-16. DOI: [10.29271/jcpsp.2018.01.13](https://doi.org/10.29271/jcpsp.2018.01.13)
  53. Goel A, Krupashankar DS, Aurangabadkar S, Nischal KC, Omprakash HM, Mysore V. Fractional lasers in dermatology-current status and recommendations. *Indian J Dermatol Venereol Leprol*. 2011;77(3):369-379. DOI:[10.4103/0378-6323.79732](https://doi.org/10.4103/0378-6323.79732)
  54. Parra CAH, Careta MF, Valente NYS, Osorio NEGdS, Torezan LAR. Clinical and Histopathologic Assessment of Facial Melasma After Low-Fluence Q-Switched Neodymium-Doped Yttrium Aluminium Garnet Laser. *Dermatologic Surgery*. 2016;42(4):507-512. DOI: [10.1097/DSS.0000000000000653](https://doi.org/10.1097/DSS.0000000000000653)
  55. Lee DB, Suh HS, Choi YS. A comparative study of low-fluence 1064-nm Q-switched Nd: YAG laser with or without chemical peeling using Jessner's solution in melasma patients. *Journal of Dermatological Treatment*. 2014;25(6):523-528. DOI: [10.3109/09546634.2013.848261](https://doi.org/10.3109/09546634.2013.848261)
  56. Vachiramon V, Sahawatwong S, Sirithanabadeekul P. Treatment of melasma in men with low-fluence Q-switched neodymium-doped yttrium-aluminum-garnet laser versus combined laser and glycolic acid peeling. *Dermatologic Surgery*. 2015;41(4):457-465. DOI: [10.1097/DSS.0000000000000304](https://doi.org/10.1097/DSS.0000000000000304)
  57. Vachiramon V, Sirithanabadeekul P, Sahawatwong S. Low-fluence Q-switched Nd: YAG 1064-nm laser and intense pulsed light for the treatment of melasma. *Journal of the European Academy of Dermatology and Venereology*. 2015;29(7):1339-1346. DOI: [10.1111/jdv.12854](https://doi.org/10.1111/jdv.12854)
  58. Cohen BE, Elbuluk N. Microneedling in skin of color: A review of uses and efficacy. *Journal of the American Academy of Dermatology*. 2016;74(2):348-355. DOI: [10.1016/j.jaad.2015.09.024](https://doi.org/10.1016/j.jaad.2015.09.024)
  59. Saleh FY, Abdel-Aziz ES, Ragaie MH, Guendy MG. Topical tranexamic acid with microneedling versus microneedling alone in treatment of melasma: clinical, histopathologic, and immunohistochemical study. *Journal of the Egyptian Women's Dermatologic Society*. 2019;16(2):89-96. DOI: [10.4103/JEWD.JEWD](https://doi.org/10.4103/JEWD.JEWD)
  60. Budamakuntla L, Loganathan E, Suresh D, Shanmugam S, Dongare A, Prabhu N, Venkataramiah L. A randomized, open-label, comparative study of tranexamic acid microinjections and tranexamic acid with microneedling in patients with melasma. *Journal of Cutaneous and Aesthetic Surgery*. 2013;6(3):139-43. DOI:[10.4103/0974-2077.118403](https://doi.org/10.4103/0974-2077.118403).



This work is licensed under a Creative Commons Attribution